



Photography in pediatric dentistry: basis and applications

Stefanie Bressan Werle^a, Fabiane Piva^b, Cristiane Assunção^c, Lizandra Ferrari Guimarães^c,
Fernando Borba de Araújo^c, Fábio Herrmann Coelho-de-Souza^d

Abstract

There is a lack in the literature regarding the production of digital images in pediatric dentistry. Some technical difficulties on the obtaining the image, such as reduced size of the oral cavity, behavioral aspects and clinical time are important features that may compromise the image quality as well as the clinical procedure. The perfect photograph in pediatric dentistry could be difficult, because repetitions can compromise the management of the child patient. However, programs and tools of images editing can be used to improve the photograph. The aim of this review was to clarify the applications of photography in pediatric dentistry. Moreover, concepts of production and images storage, the child management, adapted equipments, ethical considerations, indications of photography for research and as a diagnosis method were addressed.

Key words: Photography; Child; Diagnosis

^a Department of Pediatric Dentistry, School of Dentistry, Faculty of Serra Gaúcha, Caxias do Sul, Brazil

^b Department of Pediatric Dentistry, School of Dentistry, Lutheran University of Brazil, Cachoeira do Sul, Brazil

^c Department of Pediatric Dentistry, School of Dentistry, Federal University of Rio Grande do Sul, Porto Alegre, Brazil

^d Department of Operative Dentistry, School of Dentistry, Federal University of Rio Grande do Sul, Porto Alegre, Brazil

Fotografia em odontopediatria: base e aplicações

Resumo

Atualmente, há uma lacuna na literatura em relação à produção de imagem em odontopediatria. Algumas dificuldades na técnica, como a reduzida abertura bucal, aspectos comportamentais da criança e o tempo clínico são variáveis importantes que podem comprometer tanto a qualidade das imagens quanto o procedimento clínico em si. Uma fotografia perfeita do paciente odontopediátrico pode ser difícil de ser obtida, pois as repetições podem comprometer o manejo do paciente. No entanto, programas e ferramentas de edição de imagem podem ser usados para melhorar a qualidade da fotografia. O objetivo dessa revisão foi elucidar as aplicações da fotografia em odontopediatria, desde os conceitos de produção até o armazenamento e edição da imagem. Além disso, abordar o manejo da criança, adequação dos equipamentos, considerações éticas e indicações da fotografia como método de pesquisa e diagnóstico.

Palavras-chave: Fotografia; Criança; Diagnóstico

Correspondence:
Stefanie Bressan Werle
stewerle@hotmail.com

Received: September 8, 2014
Accepted: May 4, 2015

Conflict of Interests: The authors state that there are no financial and personal conflicts of interest that could have inappropriately influenced their work.

Copyright: © 2015 Werle et al.; licensee EDIPUCRS.

Except where otherwise noted, content of this journal is licensed under a Creative Commons Attribution 4.0 International license.



<http://creativecommons.org/licenses/by/4.0/>

Introduction

In the early '90s there was a popularization of digital cameras. The advancement in the storage of information obtained helped spread the photograph in the most diverse areas, including dentistry [1].

Although the technology is relative new, the literature reports the extensive use of digital photography in dental researches [2-6]. This advancement supports the doctor-patient relationship regarding the diagnosis, the orientations, the clinical cases and also in dental marketing.

A recent study showed that almost half (48%) of UK dentists makes use of photography in their clinical practice. Of these, 84% use images to the planning of treatment, 75% for instruction or motivation in oral hygiene, 71% to legal documentation and 64% for communication with the laboratory [7].

However, there is a lack in the literature regarding the production of digital images in pediatric dentistry. Some technical difficulties on the obtaining the image, such as reduced size of the oral cavity, behavioral aspects and clinical time are important features that may compromise the image quality as well as the clinical procedure.

Therefore, this review aimed to clarify the applications of photography in pediatric dentistry. Concepts of production and saving images, the child management, and the indications of photography as a research and diagnosis method were addressed.

Concepts of the image production

Nowadays, many types of digital photographic cameras are available to the dentists, and we can highlight the compact cameras, the semi-professional ones, and professional using (reflex) [1,8]. The best digital camera to get suitable intraoral images is the reflex model (DSLR: digital single lens reflex) [9,10]. The reflex camera is divided in two parts: body and lens, being possible to exchange the lens for a macro lens, which one takes pictures of small objects in a short distance, as we need in dentistry. The macro lens more frequently used in dentistry is 100 or 105 mm. Furthermore, reflex cameras have several options of adjustment to perform excellent photography quality and photographic standardization, besides manual focus adjustment, which is a necessity to photograph intraoral environment. However, the reflex camera requires knowledge and photographic expertise to be able to obtain suitable images. A ring flash attachment is also necessary to illuminate inside the oral cavity and make it possible to obtain intraoral images. The ring flash must be attached on the final portion of the lens (lens edge) [10].

The compact digital photographic cameras became developed in the last decades, with high quality and a fair price. Compact cameras are versatile and multifunctional equipment and easy to operate [1]. On the other hand, the use of compact cameras in dentistry is restricted and limited, because the lens is not exchangeable, the focus is automatic, and it is difficult to obtain standardized and excellent images.

The semi-professional digital photographic cameras present similar characteristics than the compact cameras. When customized with ring flash or illuminator, close-up lens filter and manual focus, the semi-professional camera could be used to obtain reasonable intraoral images. However, even adapted, the semi-professional cameras do not have the same resources and quality than reflex cameras [11].

The ethical considerations

The photograph for clinical purposes may dispense the signature of informed consent form to specific image use, because this procedure is part of the treatment protocol previously authorized by the patient. However, when the professional intends to use the image for the publishing, marketing or education purposes is essential to signing the consent form by the patients or their legal guardians [12].

It should be emphasized that digital photography presents a manipulation bias. The aim of manipulation may be to show the prognosis to the patient, as gingival contouring, whitening or esthetic reconstructions. We must make it clear that the manipulation is only an estimate and not assurance of the outcome. It is necessary to follow a skeptical approach with the photographs used in research and clinical dentistry, since the manipulation of images is not easily detected [13].

The photographer position

One particularity of obtaining clinical photography in pediatric dentistry is the necessity of an assistant, who must to hold the mirror in the mouth and to apply air jet. The assistant can be the dentist, which simultaneously controls the child's behavior. The position of the photographer may be behind or in front of the patient, depending on the preference of the operator and the ease of access to the infant patient (Figure 1A and D).

Use of light reflector associated with the flash

Many professionals do not use the light reflector for the photography. However, the light reflector may be necessary to best adjustment of manual focus. Especially when posterior teeth are involved in the image, since is dark in the oral cavity and the focus adjustment could be more difficult. The flash light is much more intense than the light originating from the reflector, and there is no interference in the image obtained.

Management of the child patient

In pediatric dentistry the time of procedure and the patient comfort are decisive factors for the treatment success. Thus, considering the need the photography and the benefit for the patient is important [12]. The repetition of photographs for a perfect intra-oral image can compromise the management of the child patient, and should be evaluated a real need

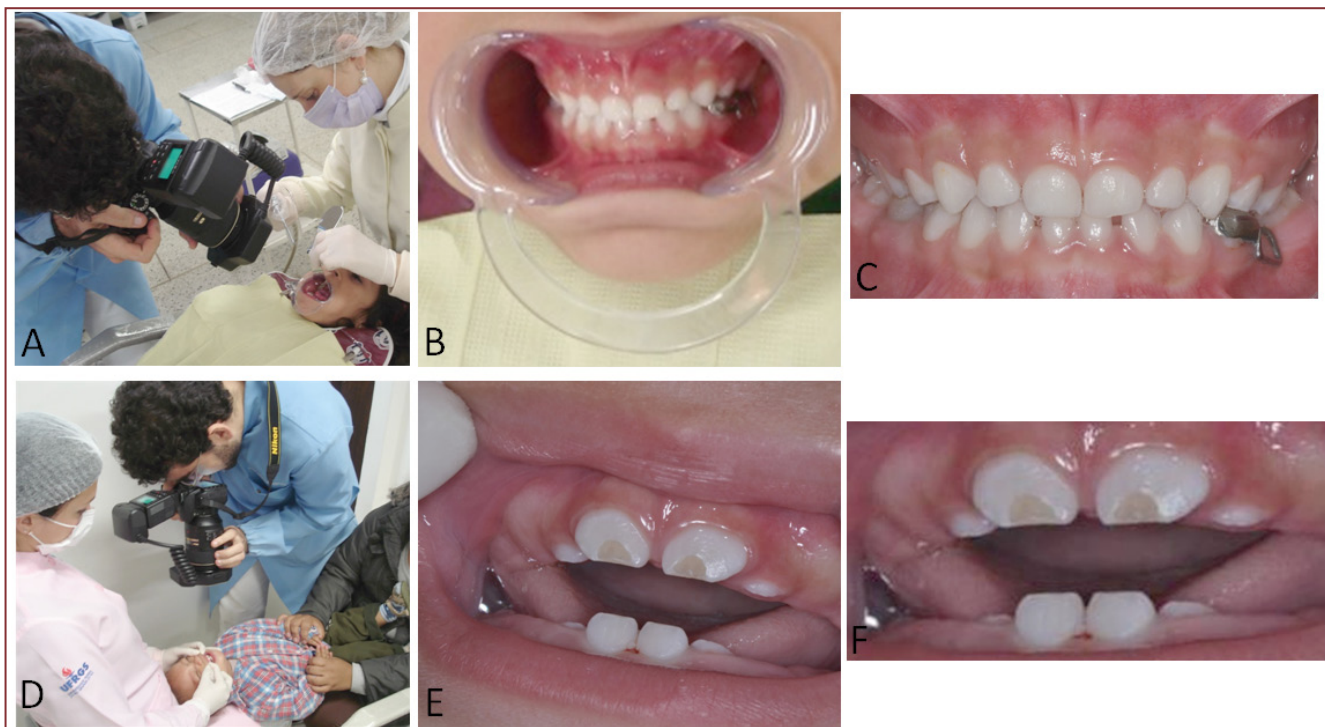


Fig. 1. A-B - Photography taken with lip retractors; D-E - Photography taken in less than ideal conditions, Pediatric dentist using her fingers to retract baby lips. C-F - The edited images through specific programs.

for a new photography. Another important factor to be considered is the clinical time increased, that is needed to obtain images of clinical sequence of procedure. Moreover, with the passage of time, the local anesthetic can be reduced and promoting greater patient discomfort.

The use of retractors adequate to the small size of the oral cavity from children is a significant step to making a good photography (Figure 2). Anyway, minimal discomfort is expected, as well as difficulties in maintaining the desired position of the child, which may negatively impact the behavior of the child patient.

The management techniques such as 'say, show and do', distraction and modeling may be used. The photography can also be used as an entertainment, comparing the common with the intra-oral images. Therefore, the children can see their images via the display of the digital camera, improving the understanding of their oral health and treatment needs [3].

Image storage and optimization

The JPEG (joint photographic experts group) format is the most widely used for storage of digital images, with a high resolution and low size, without loss of quality. This format is also recommended for clinical cases to illustrate academic presentations in PPT or Keynote. For publication purposes, the format TIFF (Tagged information file format), with high resolution and relatively large size, is the most requested by magazines and dental journals [12].



Fig. 2. Lip retractors with specific sizes to adults and children.

For legal purposes, the RAW format, which is a 'digital negative', with no possibility of manipulation, is the most suitable. This format produces an image with the date, hour and type of camera in which the photograph was made, maintaining the photograph authenticity [12].

In pediatric dentistry, sometimes the photography is not ideally performed. The operator avoids repetition in order to keep the good behavior of the child in a short clinical

time. Thus, minor adjustments such as alignment, crop, color balance, brightness, contrast, sharpen and white balance are important resources to improve the photograph quality (Figure 1 – B,C, E and F).

Some programs are available for images optimization or manipulation, such as: Picasa, Adobe Bridge, Photoshop and Dolphin. This one is specifically for use in dentistry.

Indications in pediatric dentistry

Photography can serve as a tool for managing the child's behavior and family adherence to dental treatment. Intraoral images can help children and their parents to understand the initial oral state and evolution during treatment, through visualization of cavities and their restorations.

The follow-up of clinical cases can be accomplished through photographs. Traumatized teeth may have color changes that modify according the pulp reaction, which can be registered through photography, assisting the diagnosis and follow-up these teeth. The photograph of common radiographies is also important to preserve the radiographic exam.

The photograph is also applied to register the biopsied lesions or anomalies of tooth development. Some object, such as ruler or a scalpel blade placed next to the lesion, could be used as a scale bar. Communication among dentists and dental laboratory could be done using photographs, improving orthodontics applies and prosthesis manufacturing.

Photography is also widely used to for dental education in under-graduation or post graduate classes and publication in scientific journals. The image standardization is important for this type of documentation, for aesthetic visual as well as to monitor the case evolution. The contrast (dark background) should be used to generate an image with minimum interferences, highlighting the structures of interest. The contrast is a device, usually found in dental materials stores. When we do not have access to this device, it is possible to fabricate a disposable background of black paper adapted to the child oral cavity size.

Research and photography

Recent studies have demonstrated that the digital photography is a tool for diagnosis in pediatric dentistry [2-6].

The validity and reliability of the photograph with a purpose to identify DDE (developmental defects of enamel) was evaluated in children (10-12 years old). Just one digital image was sufficient to show 91.7% of enamel lesions. This percentage increased to 99.9% when multiple images were performed (maximum of 5 images). The efficacy of photograph in the diagnosis of DDE was evident, which may be important in epidemiological and clinical follow-up of patients [2]. The alterations on enamel opacity also can be evaluated by images. Davies (2012) [6] reported the photography as a new useful method to assess the prevalence and impact on self-perception of opacity of enamel in young patients.

The use of photography for diagnosis in pediatric dentistry, as a low-cost and non-invasive method has also been evaluated [14]. Five standardized photographs were made and subsequently evaluated by four dentists. The diagnosis made through the photographs method was compared to clinical examination (gold standard). The results showed sensitivity about 94-100% and specificity between 52 and 100%. The authors concluded that the diagnostic by images is a valid instrument, but requires implementations to improve it.

For the detection of carious lesions, photography was compared with visual examination, showing similar efficacy, especially when 8 photographs were obtained and analyzed [5]. However, the time for obtaining the photograph was higher compared to visual clinical examination [4]. Children (5-11 years-old) who were evaluated by these two methods, preferred photography to visual clinical examination and also demonstrated greater interest in their oral health when photographs were performed [3]. The use of intraoral camera for caries diagnosis in preschool children is also a viable and cost effective alternative. This technique showed similar efficacy when compared with clinical examination [15].

A recent study showed the efficacy of photography to evaluate dental restorations [16]. The images allowed evaluate the integrity of the restorations, with visualization of aspects undetectable under clinical examination, significantly increasing the detection of defects. However, the use of zoom is not recommended, since may induce overtreatment.

Conclusions

Photography was incorporated in dental practice in the last years, participating of several steps of dental assistance, such as: clinical inspection, diagnosis process, treatment planning, and patients' follow-up, besides to make it easy the communication among professional colleagues.

To pediatric dentistry, photography is also important, besides all mentioned aspects, images could help and improve the communication with the children's parents and all family. It is necessary to adapt the equipment for children because their small dimensions of oral cavity.

The best digital camera to get suitable intraoral images in pediatric dentistry is the reflex model, associated with some devices, such as: macro lens, ring flash attachment and intraoral accessories to allow the oral cavity access, like lip retractors and mirrors.

References

1. Sharland MR. An update on digital photography for the general dental practitioner. *Dent Update* 2008;35:398-400.
2. Wong HM, McGrath C, Lo EC, King NM. Photographs as a means of assessing developmental defects of enamel. *Community Dent Oral Epidemiol* 2005;33:438-46.
3. Boye U, Foster GR, Pretty IA, Tickle M. Children's views on the experience of a visual examination and intra-oral photographs to detect dental caries in epidemiological studies. *Community Dent Health* 2012; 29:284-8.



4. Boye U, Willasey A, Walsh T, Tickle M, Pretty IA. Comparison of an intra-oral photographic caries assessment with an established visual caries assessment method for use in dental epidemiological studies of children. *Community Dent Oral Epidemiol* 2013;41:526-33.
5. Boye U, Pretty IA, Tickle M, Walsh T. Comparison of caries detection methods using varying numbers of intra-oral digital photographs with visual examination for epidemiology in children. *BMC Oral Health* 2013;13:6.
6. Davies GM, Pretty IA, Neville JS, Goodwin M. Investigation of the value of a photographic tool to measure self-perception of enamel opacities. *BMC Oral Health* 2012;12:41.
7. Morse GA, Haque MS, Sharland MR, Burke FJ. The use of clinical photography by UK general dental practitioners. *Br Dent J* 2010;9:E1.
8. Shagam J, Kleiman A. Technological updates in dental photography. *Dent Clin North Am* 2011;55:627-33.
9. Terry DA, Snow SR, McLaren EA. Contemporary dental photography: selection and application. *Compend Contin Educ Dent* 2008;29:432-6.
10. Shorey R, Moore K. Clinical digital photography: implementation of clinical photography for everyday practice. *J Calif Dent Assoc* 2009;37:179-83.
11. Sheridan P. Practical aspects of clinical photography: Part 1 – Principles, equipment and technique. *ANZ J Surg* 2013;83:188-91.
12. Sheridan P. Practical aspects of clinical photography: Part 2 – Data management, ethics and quality control. *ANZ J Surg* 2013;83:293-5.
13. Rao SA, Singh N, Kumar R, Thomas AM. More than meets the eye: digital fraud in dentistry. *J Indian Soc Pedod Prev Dent* 2010;28:241-4.
14. Amável R, Cruz-Correia R, Frias-Bulhosa J. Remote diagnosis of children dental problems based on non-invasive photographs – a valid proceeding? *Stud Health Technol Inform* 2009;150:458-62.
15. Kopycka-Kedzierawski DT, Billings RJ, McConnochie KM. Dental screening of preschool children using teledentistry: a feasibility study. *Pediatr Dent* 2007;29:209-13.
16. Moncada G, Silva F, Angel P, Oliveira O Jr, Fresno M, Cisternas P, Fernandez E, Estay J, Martin J. Evaluation of Dental Restorations: A Comparative Study Between Clinical and Digital Photographic Assessments. *Oper Dent* 2013;39:E45-56.

