

## Analysis by means of cone-beam computed tomography, bone density and X-ray beam attenuation of rabbit mandibles subjected to low-level laser therapy during distraction osteogenesis

Análise por meio de tomografia computadorizada de feixe cônico, densidade óssea e atenuação do feixe de raios X de mandíbulas de coelhos submetidas a terapia a laser de baixa potência durante osteogênese por distração

Rodrigo Cenci<sup>1</sup>, Vinicius Silveira<sup>2</sup>, Luciano Mayer<sup>3</sup>, Helena de Oliveira<sup>4</sup>, João Moraes<sup>5</sup>,  
Marília Gerhardt Oliveira<sup>6\*</sup>

<sup>1</sup>MSc. Researcher, Department of Oral and Maxillofacial Surgery, School of Dentistry. PUCRS; <sup>2</sup>MSc. Researcher, Department of Oral and Maxillofacial Surgery. PUCRS; <sup>3</sup>PhD. Researcher, Department of Oral and Maxillofacial Surgery, School of Dentistry. PUCRS; <sup>4</sup>PhD. Professor, School of Dentistry. PUCRS; <sup>5</sup>PhD. Professor, School of Mathematics. UFRGS; <sup>6</sup>PhD. Researcher, CNPq. Maxillofacial Surgeon, Hospital Cristo Redentor – Grupo Hospitalar Conceição. RS.

### Abstract

**Objectives:** To assess by means of cone-beam computed tomography (CBCT) the relative bone density of newly formed bone in rabbit mandibles treated with low-level laser therapy (LLLT) during distraction osteogenesis (DO). **Methods:** Seven rabbits underwent surgical osteotomy and immediate installation of a distractor on the mandible (right side). DO was performed for 10 days, and LLLT (aluminum-gallium-arsenide [AlGaAs] infrared laser,  $\lambda$  830 nm, 40 mW) was applied during distractor activation (days 4-10). Three rabbits were euthanized at the end of the activation period (day 10, group A), and four at the end of the maturation period (day 20, group B). Quality and quantity of newly formed bone in the distracted area were measured on grayscale images using adjacent untreated areas as controls. Two CBCT images were acquired for each animal (before and after removal of soft tissue) to evaluate the influence of the soft tissue on X-ray beam attenuation. **Results:** Mean grayscale values in the distracted area were higher in group B rabbits (140.47 vs. 102.55 in group A), indicating greater bone maturation in a short period. Absence of soft tissues during CBCT scanning was associated with higher grayscale values, indicative of less X-ray beam attenuation. **Conclusions:** It is possible to measure differences in bone density in areas subjected to DO on CBCT scans, providing an objective assessment useful for monitoring bone quality during the repair process.

**Keywords:** Osteogenesis. Distraction. Laser Therapy. Tomography, X-ray Computed. Bone Density.

### Resumo

**Objetivos:** Através de tomografia computadorizada de feixe cônico (TCFC), avaliar a densidade óssea relativa de tecido ósseo neoformado em mandíbulas de coelhos tratados com terapia a laser de baixa potência (LLLT) durante a osteogênese por distração (OD). **Metodologia:** Sete coelhos foram submetidos ao procedimento cirúrgico de osteotomia e instalação imediata de aparelho distrator na mandíbula (lado direito). Os animais foram submetidos à OD por dez dias e à LLLT (laser infravermelho arseneto de gálio-alumínio [AlGaAs],  $\lambda$  830 nm, 40 mW) durante o período de ativação do aparelho distrator (dias 4-10). Três coelhos foram mortos no final do período de ativação (dia 10, grupo A), e quatro no final do período de maturação (dia 20, grupo B). A qualidade e a quantidade de tecido ósseo neoformado na área da distração foram medidas em imagens em níveis de cinza usando áreas adjacentes não tratadas como controle. Duas imagens de TCFC foram obtidas para cada animal (antes e após a remoção dos tecidos moles) para avaliação da influência dos tecidos moles na atenuação do feixe de raios X. **Resultados:** Os valores médios de cinza na área da distração foram maiores nos coelhos do grupo B (140,47 versus 102,55 no grupo A), indicando maior maturação óssea em um curto período. A ausência de tecidos moles durante a TCFC estava associada a maiores valores de cinza, evidenciando menor atenuação do feixe de raios X. **Conclusões:** É possível medir diferenças na densidade óssea em áreas submetidas à OD em imagens de TCFC, fornecendo uma avaliação objetiva útil para o monitoramento da qualidade do osso durante o processo de reparo.

**Palavras-chave:** Osteogênese por Distração. Terapia a laser. Tomografia Computadorizada por Raios X. Densidade Óssea.

### INTRODUCTION

Treatment of facial deformities is still a challenge for dentistry, especially for maxillofacial surgery. Distraction osteogenesis (DO) is a treatment option for facial bone reconstruction.<sup>1</sup>

Low-level laser therapy (LLLT) has been used during DO to accelerate the process of bone maturation,<sup>2,3</sup> showing great potential to shorten treatment time, increase patient comfort, alleviate postoperative edema, and improve tissue healing.<sup>4-10</sup>

While planning treatment of these patients, it is of paramount importance to assess not only bone quantity but also its quality. One of the available methods for qualitative and quantitative assessment of new bone

**Correspondência/ Correspondence:** \*Marília Gerhardt de Oliveira, Rua Visconde do Herval, 725/404B, Bairro Menino Deus, CEP 90130-151 – Porto Alegre, RS – Brazil. E-mail: gerhardtoliveira@gmail.com. Phone: +55-51-9919.6290

formation is computed tomography (CT), which enables assessment of bone tissue density and geometry.<sup>11-13</sup>

A comparison of currently available technologies shows that cone-beam computed tomography (CBCT) has an edge over conventional CT for dental planning and treatment.<sup>14</sup> The higher sensitivity of CBCT enables us to obtain more detailed information on newly formed bone with lower radiation exposure, lower cost, less metal artifact, and less time required for image acquisition as compared to conventional, or fan beam CT (FBCT). A disadvantage of the technique is that, unlike FBCT, it still lacks adequate calibration for the Hounsfield scale and its unit (HU).<sup>14-18</sup>

In X-ray imaging, density is associated with the degree of darkening of the resulting image, and is directly related to the amount of radiation incident on the image receptor after exposure. The collision between X-ray photons and matter gives rise to beam absorption and attenuation processes, which are related to the density (attenuation coefficient) and thickness of the material of interest.<sup>15</sup> Therefore, we hypothesized that evaluation of grayscale levels obtained through CBCT imaging in the distracted area (using adjacent untreated areas as controls) would permit a quantitative measurement of relative bone density with greater accuracy, and that assessment of soft tissue influence on X-ray beam attenuation (by acquiring images before and after soft tissue removal) would enable us to validate these measurements and use them together in normal clinical situations. This, in turn, would provide us with an objective parameter to monitor bone quality during the repair process.

Kreisner et al.<sup>9</sup> conducted a histological evaluation of rabbit mandibles subjected to DO and LLLT and concluded that laser therapy had a positive effect on the percentage and quality of newly formed bone, thus allowing earlier removal of the distractor. After the bone maturation period, the percentage of newly formed bone was 57.89% in the LLLT group vs. 46.75% in the control group.<sup>9</sup>

Hübner et al.<sup>19</sup> observed that, in a group of five rabbits subjected to DO, of which three received LLLT with aluminum-gallium-arsenide (AlGaAs) during the consolidation stage, according to the analysis of the chemical composition of calcium and phosphorus, mineralization was greater in the group receiving LLLT, showing that LLLT had a positive effect on the biomodulation of newly formed bone.

This study aimed to conduct a CBCT-based assessment of relative bone density of newly formed bone in rabbit mandibles undergoing DO under the biomodulatory effect of infrared laser (AlGaAs laser,  $\lambda$  830 nm, 40 mW) irradiated during activation of the distractor. For this purpose, we quantified grayscale levels on CBCT scans in the distracted area and in adjacent untreated (control) areas and simultaneously analyzed whether the presence or absence of soft tissues would have an influence on X-ray beam attenuation in the distracted area.

## MATERIALS AND METHODS

Animal handling and experimentation followed the Brazilian Ethical Principles of Animal Experimentation and international standards and guidelines for the care and use of laboratory animals. The study was approved by the Research Ethics Committee of Pontifícia Universidade Católica do Rio Grande do Sul (PUCRS) (protocol No. 06/03522), and all possible measures were taken to minimize pain and discomfort. The experiment used only the minimum number of animals required to produce reliable scientific data.

### Animals

The sample consisted of seven male New Zealand white rabbits (order Lagomorpha, genus *Oryctolagus*, species *Oryctolagus Cuniculus*) of known adult age and weight 3.5-4.5 kg. Animals were placed into individual cages, identified with cage cards, and provided a commercially available solid diet (Purina®, Nestlé Purina Petcare, St. Louis, MO) and water ad libitum. The vivarium was climate-controlled to ensure normal lighting, relative humidity, and temperature conditions. After one week of adaptation and observation, animals were examined by the vivarium staff veterinarians and cleared for the study.

### Distraction osteogenesis (DO)

Animals were anesthetized with xylazine hydrochloride 2% (0.1 mg/kg) and tiletamine/zolazepam hydrochloride (3 mg/kg). The surgical site was shaved and prepped with a 0.5% iodophor-in-alcohol solution. The surgical field was isolated with sterile drapes. Then, local infiltration of 2 mL of 1% lidocaine/epinephrine 1:100000 was performed targeting local vasoconstriction. A 3 cm-long incision was made on the skin overlying the right inferior border of the mandible and the subcutaneous tissues dissected in layers. A monocortical osteotomy was performed posterior to the mental foramen and anterior to the premolar, using a 1.0 mm carbide bur, at low rotation, with constant normal saline irrigation. The inferior alveolar nerve was preserved. A titanium distraction device (PROMM®, Porto Alegre, Brazil) was installed on the mandible with four screws placed perpendicular to the osteotomy. After fixation, the distractor was activated for two complete turns and the osteotomy was completed with the aid of bone chisels. The wound was closed in layers. All animals received antibiotic prophylaxis with enrofloxacin 1 hour before the procedure and for the first three postoperative days.

DO was performed in three stages. During the first three postoperative days, the distractor was not activated, but merely inspected and disinfected with a 1% iodophor-in-alcohol solution (latency period, days 1-3). After the third postoperative day, the distraction device was activated in daily 0.8 mm increments over a total of seven days (approximately 5.6 mm total) (activation period, days 4-10). After the latency and activation periods, the distraction device remained in place for a further ten days, serving as an external fixator so that bone maturation could be achieved (maturation period, days 11-20).

### Low-level laser therapy (LLLT)

During the activation period, LLLT was applied in all animals to three points overlying the site of DO, at an energy density of 4 J/cm<sup>2</sup> per point, with the irradiation tip placed perpendicularly over the area, for a total dose of 12 J/cm<sup>2</sup> per session. An AlGaAs infrared laser (TheraLase<sup>®</sup>, DMC Equipamentos, São Carlos, SP, Brazil) was used at a wavelength of 830 nm, with 40 mW output power, and continuous wave irradiation for a spot application time of 00:01:41 (101 seconds, automatically controlled by the laser device as determined by other parameters). The irradiation protocol was instituted immediately after activation of the distractor and repeated every 48 hours thereafter, for a total of four sessions and a total dose of 48 J/cm<sup>2</sup>.

### Randomization

The rabbits were randomly divided into two groups for euthanasia: Group A (n=3), euthanized at the end of the activation period (on postoperative day 10); and Group B (n=4), euthanized at the end of the maturation period (on postoperative day 20). All animals were euthanized by deep anesthesia with xylazine hydrochloride 2% (0.1 mg/kg body weight) and tiletamine/zolazepam hydrochloride (3 mg/kg body weight), leading to cardiopulmonary arrest. After confirmation of death by absence of vital signs, the mandibles were removed, isolated, separated, and labeled for physical evaluation. Specimens were embedded in a 2% glutaraldehyde solution.

### Study endpoints

Quality and quantity of newly formed bone in the distracted area were measured by quantifying grayscale levels on CBCT scans of all seven rabbit mandibles. Untreated areas adjacent to the distracted area were also assessed and used as controls. In each rabbit, two CBCT images were acquired (one before and one after soft tissue removal) for assessment of soft tissue influence on X-ray beam attenuation in the distracted area.

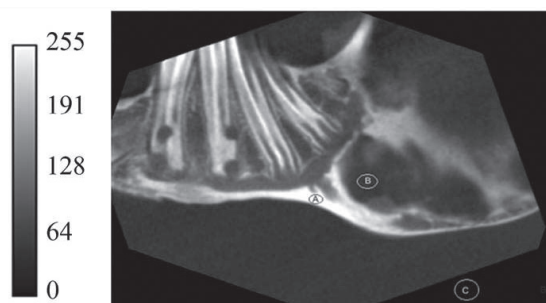
### Cone-beam computed tomography (CBCT)

A prototyped CT guide was used to aid image acquisition. Rabbit mandibles were placed onto the guide (specially designed for this purpose), with a millimeter scale along the coronal axis and a midline indicator, so that the beam of the CBCT scanner's light localizer could be kept at the same angle over all specimens during all acquisitions. A positioning device was also used to place the mandibular central incisors onto the guide, thus providing reproducibility as for positioning of the mandibles during image acquisition.

The acquired images were stored in the Digital Imaging and Communications in Medicine (DICOM) file format. Measurements of relative bone density in the area of newly formed bone were analyzed using the ImageJ free-ware program, developed by the U.S. National Institutes of Health. ImageJ enabled us to correlate the grayscale levels with the attenuation coefficients of the X-ray beam in the distracted area and in the body of the mandible in

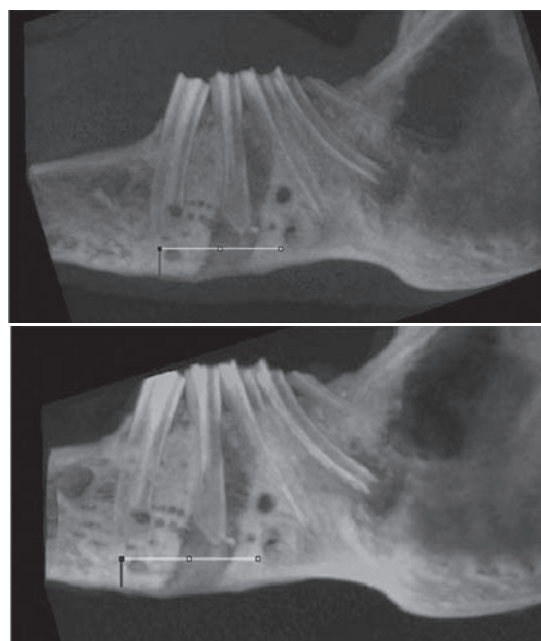
all rabbits. Values were entered into Microsoft Excel for Windows<sup>®</sup> spreadsheets for analysis.

Processing in the ImageJ suite required image conversion to 8-bit grayscale (256 shades of gray). A scale of gray levels from 0 to 255 was defined for each image, where 0 (zero) represents the darkest shade of gray (black) and 255 the lightest shade of gray (white). Lower grayscale values (darker levels) correspond to less attenuation of the X-ray beam during exposure and higher grayscale values (lighter levels) to greater attenuation (Figure 1).



**Figure 1** – Grayscale obtained from images acquired with the Carestream TC K9000<sup>®</sup> Cone Beam CT Scanner. Point A represents grayscale values of 255, point B represents grayscale values in the 60 to 70 range, and point C represents grayscale values of 0 (zero).

To standardize CBCT image analysis, scans were three-dimensionally reconstructed in the ImageJ suite. In the 3D image, linear representations were constructed at the base of the mandible to determine bone density on the scans of all seven rabbits obtained before and after soft tissue removal (Figure 2). The reference line coursed through the distracted area, but began and ended outside it.



**Figure 2** – Choice of points of analysis for each cone-beam computed tomography (CBCT) image. Yellow line denotes the linear representation used for analysis at the base of the mandible. Left: 3D reconstruction of a rabbit mandible with soft tissues. Right: 3D reconstruction of the same mandible without soft tissues.



Linear representations were 11.25 mm long and reproduced 147 points, which were used for analysis of X-ray beam attenuation during CBCT image acquisition. After obtaining grayscale values for these 147 points (i.e., along the entire length of the line marked on the image), we compared relative bone density in the distracted area and adjacent untreated areas (controls) before and after soft tissue removal. These graphs were plotted in ImageJ, generating three areas of interest for our analysis. The central portion (around the midpoint of the demarcation line) exhibited values that corresponded to relative bone density of new bone tissue formed during DO under the biomodulatory effect of LLLT, and was called 'distraction density area' (DDA). The two portions at the ends (around the farthest points from the mesial and distal of the same line) exhibited values that corresponded to relative bone density of untreated bone tissue remaining in the rabbit mandibles, and were called 'control density area' (CDA, mesial and distal).

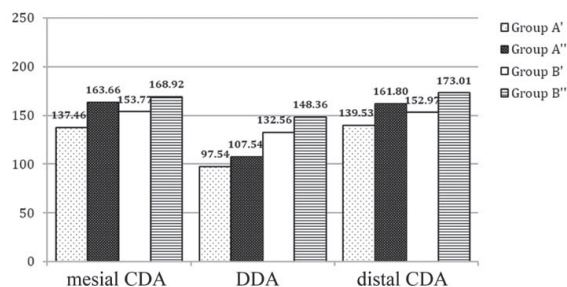
### Statistical analysis

Biostat 5.0 was used to evaluate replicability with the intraclass correlation coefficient (ICC) in the measurement of grayscale levels on CBCT scans before and after soft tissue removal. Agreement between measurements was assessed with Fleiss' kappa within Biostat 5.0. This analysis revealed agreement between measurements, with  $p < 0.0001$  for all rabbits, indicating high replicability in this study.

Analysis of variance (ANOVA) was used to assess within-group mean grayscale values obtained at the experimental area (DDA) and control areas (mesial and distal CDA). Also, grayscale levels were compared between group A rabbits (euthanized 10 days after the start of distraction) and group B rabbits (euthanized 20 days after the start of distraction) with and without soft tissues. In this analysis, a mean value between the mesial and distal CDA was calculated and used as the control parameter. All statistical analyses were performed in the SPSS 17.0 (SPSS Inc., Chicago, IL). The level of significance was set at 5% ( $p \leq 0.05$ ).

### RESULTS

The mean grayscale values obtained at the distracted area (DDA) and adjacent untreated areas (mesial and distal CDA) on CBCT images of rabbit mandibles before and after soft tissue removal are shown in Figure 3. Mandibles with soft tissues (groups A' and B') exhibited mean grayscale levels lower than those of the same rabbits without soft tissues (groups A'' and B''). There was a decrease in mean grayscale levels in the DDA as compared to the mesial and distal CDA.



**Figure 3** – Graph showing mean grayscale values obtained at the distracted area (distraction density area, DDA) and the two adjacent untreated areas (control density area, CDA) on cone-beam computed tomography (CBCT) images for the different groups: Group A' (rabbits euthanized 10 days after the start of distraction and CBCT performed **before** soft tissue removal); Group A'' (rabbits euthanized 10 days after the start of distraction and CBCT performed **after** soft tissue removal); Group B' (rabbits euthanized 20 days after the start of distraction and CBCT performed **before** soft tissue removal); Group B'' (rabbits euthanized 20 days after the start of distraction and CBCT performed **after** soft tissue removal).

Table 1 – describes grayscale values obtained at the DDA and CDA (a mean value between mesial and distal CDA) in all rabbit mandibles and used to compare X-ray beam attenuation occurring during CBCT image acquisition in relation to the presence or absence of soft tissues. In this analysis, the 10-day bone maturation period (groups B' and B'') caused the grayscale levels within the distracted area to be always higher than those found in rabbits from the group in which bone maturation was not expected (groups A' and A'').

**Table 1** – Comparison of grayscale values quantified on cone-beam computed tomography (CBCT) images in the distracted area (DDA) and adjacent untreated area (CDA) in rabbit mandibles before and after soft tissue removal.

Sample		Control density area (CDA)	Distraction density area (DDA)	
Mandibles WITH soft tissues	Group A	Rabbit 1'	130.35	79.73
		Rabbit 2'	144.75	82.73
		Rabbit 3'	140.40	130.18
	Group B	Rabbit 4'	157.35	171.36
		Rabbit 5'	146.40	123.18
		Rabbit 6'	156.15	128.09
		Rabbit 7'	153.60	107.64
Mandibles WITHOUT soft tissues	Group A	Rabbit 1''	147.20	90.82
		Rabbit 2''	168.40	82.73
		Rabbit 3''	172.60	149.09
	Group B	Rabbit 4''	165.10	182.64
		Rabbit 5''	156.05	140.36
		Rabbit 6''	192.90	155.73
		Rabbit 7''	169.80	114.73

**Group A** (n=3): rabbits euthanized on postoperative day 10 (end of the distractor activation period); **Group B** (n=4): rabbits euthanized on postoperative day 20 (end of the bone maturation

period). The rows provide grayscale values for the same sample of rabbits (a) numbered 1' to 7' when CBCT was performed before soft tissue removal and (b) numbered 1'' to 7'' when CBCT was performed after soft tissue removal. Grayscale levels ranged from 0 (zero) to 255, where 0 (zero) represents the darkest and 255 the lightest shade of gray. Lower values correspond to less attenuation and higher values to greater attenuation of the X-ray beam during exposure.

## DISCUSSION

Given the growing interest of dental professionals in CT imaging and image quality, we chose CBCT as the imaging modality for this study.<sup>20</sup> As compared to conventional CT, CBCT has the ability to provide more detailed qualitative and quantitative information on the bone present in newly formed areas, which is traditionally considered an immature bone, allowing more accurate measurement of bone density and its variations across the elongated bone segment.<sup>9</sup> In this study, CBCT enabled us to assess the quality and quantity of new bone tissue formed during DO under the biomodulatory effect of LLLT, even in the early stages of new bone formation.

Despite all the benefits of DO, this technique may cause some discomfort to the patient, particularly when external distractors are used. To address this issue, LLLT has been successfully used to accelerate the tissue repair process during DO, providing a more comfortable postoperative course and additional benefits to the healing process.<sup>10,21</sup> The early stages of DO are critical determinants of treatment success. Thus, both the application of LLLT to accelerate the repair process and use of a noninvasive technique to evaluate the progress of the healing process are of utmost importance in the management of these patients.

Some studies have shown that the effect of LLLT during the distractor activation phase led to higher rates of new bone formation in the distraction zone when compared to laser irradiation during the consolidation phase.<sup>9,10</sup> Nevertheless, a protocol for the optimal timing for LLLT biostimulation during DO has yet to be defined.

In all animals in our study, LLLT was applied to the site of DO immediately after the latency period, during distractor activation (postoperative days 4-10). Then, in order to assess the early stages of new bone formation in the distracted area, rabbits in group A were euthanized ten days after installation of the distractor (end of the activation period, postoperative day 10), whereas those in group B were euthanized 10 days later (end of the maturation period, postoperative day 20). This consolidation period, although shorter than that described in other studies using fixation periods of 14 to 42 days,<sup>12,22,23</sup> enabled us to evaluate, based on CBCT images, the initial stages of bone formation during DO. This method is supported by the results of previous studies showing new bone formation after a consolidation period of only 8 days.<sup>24</sup> We believe that, for the purposes of this study, the chosen length of the consolidation period was optimal, as complete

union and partial corticalization of newly formed bone is estimated to occur on week 4 post-DO in an experimental rabbit model.<sup>19</sup>

Mean grayscale values on CBCT images in the distracted area were higher among rabbits in group B (140.47; range, 107.64–182.64) as compared to those in group A (102.55; range, 79.73–149.09), indicating greater bone maturation in a short period. During the consolidation period, bone density increases progressively until week 4, and plateaus between weeks 6 and 8.<sup>25</sup>

The presence of soft tissues promoted a reduction in grayscale values due to attenuation of the X-ray beam. Katsumata et al.<sup>24</sup> correlated X-ray beam attenuation with the density and thickness of the exposed material. In our study, in all animals, grayscale values were lower on CBCT images acquired before soft tissue removal. However, in group B, grayscale levels in the distracted area (DDA) were closer to those measured at points outside the distracted area (mesial and distal CDA), due to the length of the maturation period applied to this group (euthanasia ten days after the end of the distractor activation period), as also previously reported by Smith et al.<sup>25</sup> Bone maturation contributes to greater attenuation of the X-ray beam, thus increasing grayscale levels on the resulting image.

The resolution and detail level of images acquired with CBCT scanners have proven adequate for use in dentistry.<sup>8,26-29</sup> In this study, CBCT imaging was able to detect even slight changes in the calcification process within only 10 and 20 days after the start of distraction, changes that would be undetectable by conventional CT. The technical parameters used here—latency, rate, and frequency—allowed for bone formation in the distraction gap, as shown by gross visualization of the resected mandibles and by CBCT imaging, thus ratifying the use of this protocol.<sup>10</sup>

The main issue discussed here was whether evaluation of grayscale levels obtained through CBCT imaging (with and without soft tissue) would allow accurate evaluation of the quality and quantity of newly formed bone even in the early stages of DO under the biomodulatory effect of LLLT, a hypothesis that could be supported by the present results.

Under our experimental conditions, it is possible to evaluate and measure differences in bone density in areas subjected to DO and to LLLT using images acquired with a CBCT scanner and adjacent untreated areas as controls, providing an objective assessment useful for monitoring bone quality during the photobiomodulated repair process following DO. In addition, the presence of soft tissues during acquisition of CBCT images contributes to a decrease in grayscale values. This decrease in grayscale values is due to attenuation of the X-ray beam as it traverses the soft tissues during scanning. This attenuation makes the X-ray beam weaker when it reaches bone—hence the lower grayscale values obtained on images acquired before soft tissue removal. This observation, however, does not preclude the assessment of bone density changes even in the early stages of new bone formation during DO, allowing the indication of CBCT for clinical diagnostic

*purposes during bone healing and maturation in the initial stages of DO. Moreover, bone density in the distracted area, as visualized on 3D reconstructions of the mandible, increases proportionally to the length of the post-DO bone maturation period.*

## CONCLUSION

*It is possible to measure differences in bone density in areas subjected to DO on CBCT scans, providing an objective assessment useful for monitoring bone quality during the repair process.*

## REFERENCES

1. MOFID, M. M. et al. Craniofacial distraction osteogenesis: a review of 3278 cases. **Plast. reconstr. surg.**, Baltimore, v. 108, n. 5, p. 1103-17, 2001.
2. VALIATI, R. et al. Effect of low-level laser therapy on incorporation of block allografts. **Int. j. med. sci.**, Blue Haven, v. 9, n. 10, p. 853-61, 2010.
3. CERQUEIRA, A. et al. Bone tissue microscopic findings related to the use of diode laser (830 nm) in ovine mandible submitted to distraction osteogenesis. **Acta cir. bras.**, São Paulo, v. 22, n. 2, p. 92-97, 2007.
4. MESTER, E. et al. Effect of laser rays on wound healing. **Am. j. surg.**, New York, v. 122, n. 4, p. 532-535, 1971.
5. SILVA JÚNIOR, A. N. et al. Computerized morphometric assessment of the effect of low-level laser therapy on bone repair: an experimental animal study. **J. clin. laser Med. surg.**, New York, v. 20, n. 2, p. 83-7, 2002.
6. WEBER, J. B. et al. Laser therapy improves healing of bone defects submitted to autologous bone graft. **Photomed. laser surg.**, Larchmont, v. 24, n. 1, p. 38-44, 2006.
7. FRONZA, B. et al. Assessment of the systemic effects of low-level laser therapy (LLLT) on thyroid hormone function in a rabbit model. **Int. j. oral maxillofac. surg.**, Copenhagen, v. 42, n. 1, p. 26-30, 2013.
8. TAKEDA, Y. Irradiation effect of low-energy laser on alveolar bone after tooth extraction: experimental study in rats. **Int. j. oral maxillofac. surg.**, Copenhagen, v. 17, n. 6, p. 388-391, 1988.
9. KREISNER, P. E. et al. Histological evaluation of the effect of the low-level laser on distraction osteogenesis in rabbit mandibles. **Med. oral patol. oral cir. bucal**, Valencia, v. 15, n. 4, p.616-618, 2010.
10. FREDDO, A. L. et al. A preliminary study of hardness and modulus of elasticity in sheep mandibles submitted to distraction osteogenesis and low-level laser therapy. **Med. oral patol. oral cir. bucal**, Valencia, v. 17, n. 1, p.102-107, 2012.
11. SWENNEN, G. R. et al. Assessment of the distraction regenerate using three-dimensional quantitative computer tomography. **Int. j. oral maxillofac. surg.**, Copenhagen, v. 34, n. 1, p. 64-73, 2005.
12. ARONSON, J. et al. Preliminary studies of mineralization during distraction osteogenesis. **Clin. orthop. relat. res.**, Philadelphia, n. 250, p. 43-49, 1990.
13. ZIMMERMANN, C. E. et al. Assessment of bone formation in a porcine mandibular distraction wound by computed tomography. **Int. j. oral maxillofac. surg.**, Copenhagen, v. 33, n. 6, p. 569-574, 2004.
14. MAH, P.; REEVES, T. E.; MCDAVID, W. D. Deriving Hounsfield units using grey levels in cone beam computed tomography. **Dentomaxillofac. Radiol.**, London, v. 39, n. 6, p. 323-325, 2010.
15. KATSUMATA, A. et al. Image artifact in dental cone-beam CT. **Oral surg. oral med. oral pathol. oral radiol. endod.**, London, v. 101, n. 5, p. 652-657, 2006.
16. NING, R. et al. Flat panel detector-based cone beam volume CT angiography imaging: system evaluation. **IEEE trans. med. Imaging.**, New York, v. 19, n. 9, p. 949-963, 2000.
17. NORTON, M. R.; GAMBLE, C. Bone classification: an objective scale of bone density using the computerized tomography scan. **Clin. oral implants res.**, Copenhagen, v. 12, n. 1, p. 79-84, 2001.
18. SIEWERDSEN, J. H.; JAFFRAY, D. A. A ghost story: spatio-temporal response characteristics of an indirect-detection flat-panel imager. **Med. phys.**, Lancaster, v. 26, n. 8, p. 1624-1641, 1999.
19. HÜBLER, R. et al. Effects of low-level laser therapy on bone formed after distraction osteogenesis. **Lasers med. sci.**, London, v. 25, n. 2, p. 213-219, 2010.
20. STEWART, K. J. et al. Mandibular distraction osteogenesis: a comparison of distraction rates in a rabbit model. **J. Craniomaxillofac. surg.**, Edinburgh, v. 26, n. 1, p. 43-49, 1998.
21. KAZEM SHAKOURI, S. et al. Effects of low-level laser therapy on the fracture healing process. **Lasers med. sci.**, London, v. 25, n. 1, p. 73-77, 2010.
22. DJASIM, U. M. et al. Histomorphometric comparison between continuous and discontinuous distraction osteogenesis. **J. Craniomaxillofac. surg.**, Edinburgh, v. 37, n. 7, p. 398-404, 2009.
23. ZHENG, L. W.; MA, L.; CHEUNG, L. K. Changes in blood perfusion and bone healing induced by nicotine during distraction osteogenesis. **Bone**, New York, v. 43, n. 2, p. 355-361, 2008.
24. KATSUMATA, A. et al. Effects of image artifacts on gray-value density in limited-volume cone-beam computerized tomography. **Oral surg. oral med. oral pathol. oral radiol. endod.**, London, v. 104, n. 6, p. 829-836, 2007.
25. SMITH, S.W.; SACHDEVA, R. C.; COPE, J. B. Evaluation of the consolidation period during osteodistraction using computed tomography. **Am. j. orthod. dentofacial orthop.**, St. Louis, v. 116, n. 3, p. 254-263, 1999.
26. MILORO, M.; MILLER, J. J.; STONER, J. A. Low-level laser effect on mandibular distraction osteogenesis. **J. oral maxillofac. surg.**, Philadelphia, v. 65, n. 2, p. 168-176, 2007.
27. MEYER, U. et al. The effect of magnitude and frequency of interfragmentary strain on the tissue response to distraction osteogenesis. **J. oral maxillofac. surg.**, Philadelphia, v. 57, n. 11, p. 1331-1341, 1999.
28. AL RUHAIMI, K. A. Comparison of different distraction rates in the mandible: an experimental investigation. **Int. j. oral maxillofac. surg.**, Copenhagen, v. 30, n. 3, p. 220-227, 2001.
29. KOMURO, Y. et al. The histologic analysis of distraction osteogenesis of the mandible in rabbits. **Plast. reconstr. surg.**, Baltimore, v. 94, n. 1, p. 152-159, 1994.

Submetido em: 31.03.2015

Aceito em: 13.05.2015