

Verrucous epidermal nevus manifesting as nipple and areola hyperkeratosis*

*Nevo epidérmico manifestando-se como hiperqueratose do mamilo e aréola**

Roberto Rheingantz da Cunha Filho¹
André Cartell³

Hiram Larangeira de Almeida Jr²

Abstract: A rare case of a 13-year-old female patient with epidermal verrucous nevus on the right areola is reported. According to the Levy-Franckel classification, this variant is a type I nipple and areola hyperkeratosis, when associated to verrucous nevus. Histopathological examination showed papillomatosis, acanthosis and hyperkeratosis. Cryotherapy yielded unsatisfactory results after two sessions. A good result was obtained with shaving and electrocauterization.

Keywords: Cryotherapy; Electrocoagulation; Epidermis; Keratosis; Nevus; Nipples

Resumo: Relata-se caso raro de nevo epidérmico na aréola mamária direita de menina de 13 anos. Segundo a classificação proposta por Levy-Franckel, essa variante é a hiperqueratose do mamilo e aréola do tipo I, quando associada a nevo verrucoso. A histologia mostrou papilomatose, acantose e hiperqueratose. Foram realizadas duas sessões de crioterapia sem melhora. Foi obtido bom resultado por meio de shaving e eletrocauterização.

Palavras-chave: Ceratose; Crioterapia; Eletrocoagulação; Epiderme; Mamilos; Nevo

Nipple and areola hyperkeratosis (NAH) is a rare affection, characterized by papillous, verrucous or filiform hyperpigmented lesions, of variable etiology, which affect this topography. First description was made in 1923 by Tauber.¹ Levy-Franckel² proposed, in 1938, the following classification: type I, extension of verrucous epidermal nevus; type II, associated with dermatoses (ictiosis, acanthosis nigricans, lymphomas, Darier's Disease); and type III, idiopathic or nevoid. There are few reports in the world literature and none in Brazil. Here we present a case of type I NAH.

Thirteen-year-old female patient, who reported the onset of asymptomatic cutaneous lesions in left breast at eleven years of age. History and physical examination did not reveal any other lesions. She denied use of medication. Menarche occurred at twelve.

Blood count, platelet count and fasting blood glucose were normal. Family history did not indicate any diseases.

Examination revealed a brownish verrucous plaque, disposed linearly, with the longest axis in the horizontal position, following Blaschko lines. Compromising beyond the limits of areola and nipple was noticed (Figure 1A). After incisional biopsy and anatomopathological examination, two cryotherapy sessions were performed, with no improvements. Lesion shaving and electrocauterization eliminated the problem, with a reasonable esthetic result (Figure 1B). Patient was very much satisfied.

Histology demonstrated a hyperkeratotic, acanthotic skin, with papillomatosis and perinuclear vacuolization. There was an absence of viral inclusions (Figure 2).

Received on January 11, 2005.

Approved by the Consultative Council and accepted for publication on June 13, 2006.

* Work done at Universidade Católica de Pelotas - UCPel - e Universidade Federal de Pelotas - Pelotas (RS), Brazil.

Conflict of interests: None

¹ Master in Health and Behavior at the Universidade Católica de Pelotas - UCPel - Pelotas (RS); Dermatologist at Centro de Especialidades Médicas de Joaçaba - CEM - Joaçaba (SC), Brazil.

² PhD in Dermatology, Professor of Dermatology at the Universidade Federal de Pelotas - UCPel - e da Universidade Católica de Pelotas - Pelotas (RS); Professor and Coordinator of the Graduate Studies Program - Master's Degree in Health and Behavior at Universidade Católica de Pelotas - Pelotas (RS), Brazil.

³ Professor of Pathology at the Universidade Federal do Rio Grande do Sul - UFRGS - Porto Alegre (RS), Brazil.

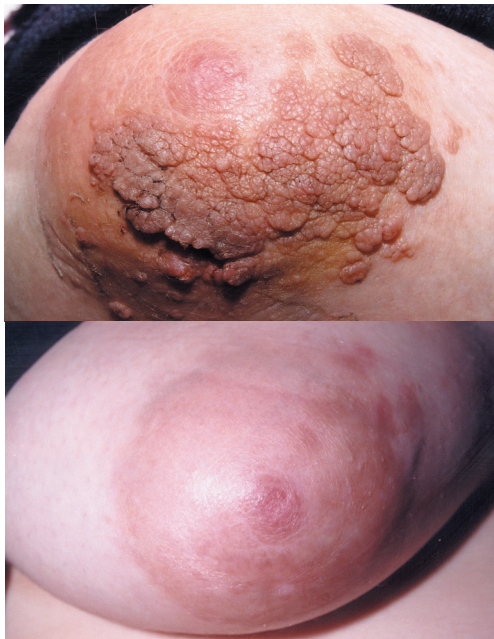

FIGURE 1: A - Epidermal nevus on the areola and surrounding skin. B - Clinical aspect 90 days after shaving and electrocauterization

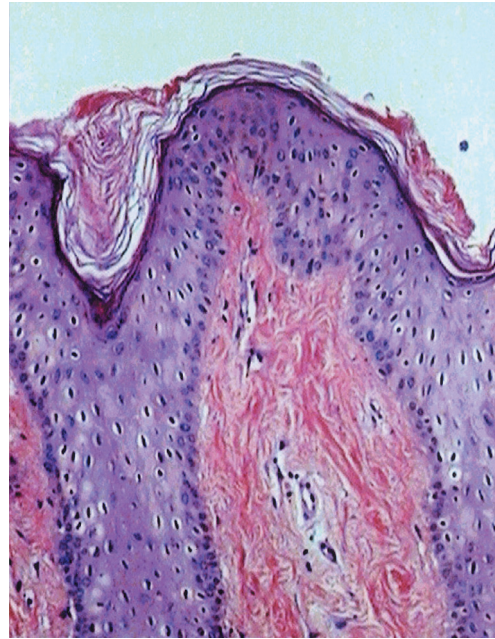


FIGURE 2: Histological aspect of the lesion (100X HE): hiperkeratosis, acantho0sis, papillomatos and perinuclear vacuolizations

Nipple and areola hyperkeratosis (NAH) is rare, with only around 60 described cases in the literature up to the date. There is no consensus regarding classification; still, the most widely used is the Levy-Franckel one,² which distributes the disease in to three categories:

Type I, extension of epidermal nevus. Type of the case presently in question. It is a verrucous nevus taking the topography of nipple and/or areola. It has a tendency of linear disposition, following the Blaschko lines, compromising trunk skin, also affecting areolar and/or nipple region, generally unilateral. Very little reported.^{2,3}

Type II, originally associated to ictiosis. It also has associations with acanthosis nigricans, Darier’s Disease, chronic eczema, lymphomas, hormonal disorders, neoplasms and graft versus host disease.^{2,4}

Type III is the nevoid form, the most published. Lesions are restricted to areola and/or nipple, generally unilateral, with no association with other diseases (isolated defect), affecting more women in the second and third decades of life.^{2,5}

Another classification has been proposed by Pérez-Izquierdo et al., 1990.⁶ It is a mistaken classification, because it used the term “systemic” for diseases that are not: ictiosis and Darier’s disease.

The most recent proposal was made by Mehanna et al., in 2001.⁷ It suggested the exclusion of epidermal nevus as a form of NAH, as well as of the term ‘nevoid’.

In spite of all that, Levy-Franckel classification² remains as the reference. The other proposals have not been adopted by any author up to the moment.

Epidermal verrucous nevus can present a great variety of histological patterns; however, hyperkeratosis, acanthosis and papillomatosis are almost always found. Baykal and colaborators⁸ carried out a case series study and verified all three alterations in all nevoid lesions of NAH. Perinuclear vacuolizations can occur in 5 to 19% of epidermal nevi.⁹ In the present case, they differed from viral inclusions, because there were no cytopathic alterations of this origin.

Course of disease is usually benign; however, emotional, sexual and functional impacts should be considered. In instances where neoplasm is present, systemic affection dictates prognosis.

Available evidence is little and based only in reports or case series. Results are variable, with the use of keratolytics, retinoic acid, calcipotriol, cryotherapy, CO₂ laser or plastic surgery.¹⁰ In the reported case, a good esthetical result was obtained with shaving followed by electrocauterization, a yet unheard-of combination in the literature for this type of problem. □

ACKNOWLEDGEMENT

A written consent was obtained from both the patient and her legal representative for publication.

REFERENCES

1. Oberste-Lehn H. Hyperkeratosen im Beereich von mamille und areola. *Z Haut Geschlechtskr.* 1950;8:388-93.
2. Levy-Franckel A. Les hyperkeratoses de l'areole et du mamelon. *Paris Med.* 1938;28:63-6.
3. Baz K, Kokturk A, Kaya TI, Ikizoglu G, Düsmesz D, Koca A. A case of hyperkeratosis of the nipple and areola resulting from organoid nevus. *Int J Dermatol.* 2003;42:318-20.
4. Sanli H, Ekmekci P, Kusak F, Arat M, Beksaç M. Hyperkeratosis of the nipple associated with chronic graft versus host disease after allogeneic haematopoietic cell transplantation. *Acta Derm Venereol.* 2003;83:385-6.
5. Xifra M, Lagodin C, Wright D, Abbruzzese M, Woscoff A. Nevoid keratosis of the nipple. *J Am Acad Dermatol.* 1999;41:325-6.
6. Perez-Izquierdo JM, Vilata JJ, Sanchez JL, Gargallo E, Millan F, Aliaga A. Retinoic acid treatment of nipple hyperkeratosis. *Arch Dermatol.* 1990;126:687-9.
7. Mehanna A, Malak JA, Kibbi AG. Hyperkeratosis of the nipple and areola. *Arch Dermatol.* 2001;137:1327-8.
8. Baikal C, Büyükbabani N, KavakA, Alper Murat. Nevoid hyperkeratosis of nipple and areola: a distinct entity. *J Am Acad Dermatol.* 2002;46:414-8.
9. Atherton DJ. Naevi and other developmental defects. In: Champion RH, Burton JL, Burns DA, Breathnach SM, eds. *Rook/ Wilkinson/ Ebling Textbook of Dermatology.* 6th ed. Oxford: Blackwell Science; 1998. p. 523-6.
10. Krishnan RS, Angel TA, Roark TR, Hsu S. Nevoid hyperkeratosis of the nipple and/or areola: a report of two cases and a review of the literature. *Int J Dermatol.* 2002;41:775-7.

MAILING ADDRESS:

*Roberto Rbeingantz Cunha Filho
Rua Roberto Trompowsky 194 - Centro
89600-000 - Joaçaba - SC - Brazil
Tel./Fax: +55 (49) 3522-1269
E-mail: robertodermatologista@botmail.com*