

# Topiramate is effective for status epilepticus and seizure control in neuraminidase deficiency

José Augusto Bragatti<sup>1</sup>, Carolina Machado Torres<sup>1</sup>, Cristina Brinckmann Oliveira Netto<sup>2</sup>, Leonardo Vedolin<sup>3</sup>, Eliana Garzon<sup>4</sup>, Carlos Roberto de Mello Rieder<sup>1</sup>, Ida Vanessa Doederlein Schwartz<sup>2,5</sup>, Marino Muxfeldt Bianchin<sup>1</sup>

Sialidosis, a rare lysosomal storage disorder is caused by a deficiency of the enzyme  $\alpha$ -N-acetyl neuraminidase, resulting from mutations in the *NEU1* gene<sup>1-5</sup>. Its main phenotypes are Sialidosis types I (milder form) and II (earlier onset)<sup>1-5</sup>. Sialidosis type II is characterized by developmental delay, macular cherry-red spot, visceromegaly, coarse facies, dysostosis multiplex, and myoclonus<sup>1-5</sup>. We report a case of status epilepticus (SE) in a patient with Sialidosis type II which had good response to topiramate.

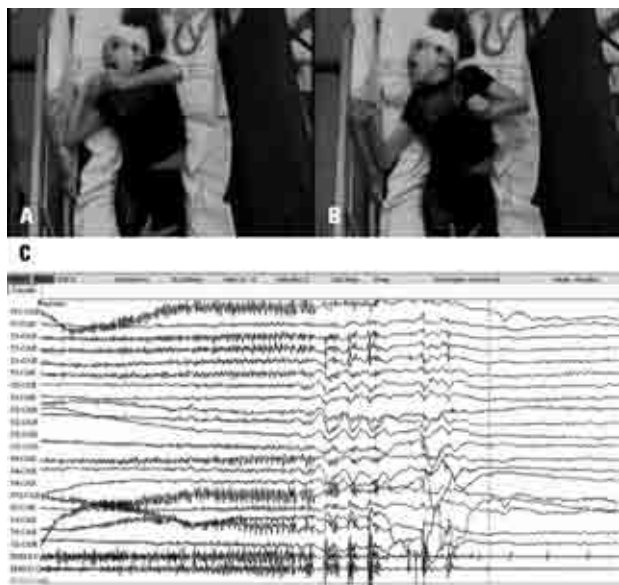
## CASE

A 16 years-old girl was admitted to our emergency unit with SE. She was using valproate 30 mg/Kg/day, primidone 10 mg/Kg/day, and clobazam 0.20 mg/Kg/day (maximum tolerated doses). Sialidosis type II was diagnosed nine years before, by detection of high levels of urinary sialil-oligosaccharides, and deficient neuraminidase activity in leukocytes. Myoclonic seizures started at the age of eleven, and further became refractory to pharmacological treatment. Before admission, she was presenting weekly myoclonic seizures. She had neuropsychological delay, short stature, mild dysostosis multiplex, and a cherry-red spot on retinal exam. Intravenous midazolam was increased till 0.4 mg/kg/hour without any benefit. MRI revealed cerebellar and brain atrophy. Interictal EEG showed multifocal spikes, mainly

involving bilateral parassagittal regions. Seizures were easily provoked by tactile stimulus, and characterized by an extensor tonic spasm in four extremities, followed by tonic arms flexion and facial muscle contraction. These movements were followed by several massive generalized myoclonic jerks (Figure). Ictal EEG showed a train of 15 Hz rhythmic spikes, predominantly in frontal regions, rapidly evolving to a polyspike-slow wave complex with fast fading away, and replaced by a generalized depression of the background activity. Seizures occurred every 5 minutes, with total duration of 30 seconds. Valproic acid was increased to 75 mg/Kg/day without benefit. Next day, we introduced topiramate 2.5 mg/Kg/day. There was improvement in seizure control, and 8 hours later patient was seizure-free. After discharge, she used this scheme for two years, with brief myoclonic jerks occurring in a monthly frequency.

## DISCUSSION

Drugs used for treatment of SE are phenytoin, benzodiazepines, phenobarbital, and propofol<sup>1,2</sup>, but treatment of SE in myoclonic progressive epilepsies is still not established. Midazolam was not effective here. Other options were propofol or barbiturates. Phenobarbital was already in use. Propofol is useful during acute phase but is not an option for long-term seizure control. Phenytoin could aggravate the myoclonic seizures of our patient.



**Figure.** Seizure lasting 30 seconds. Figures show flexion of superior limbs and jerks of facial muscles in [A]. [B] is showing massive clonic jerks. In [C] ictal EEG is showing a train of 15 Hz rhythmic spikes that predominates in frontal regions. Rhythm rapidly evolved to a polyspike-slow wave complex and then faded away.

For the same reason, benzodiazepines would not be an option, because tonic seizures, a not uncommon type of seizure in the epileptic encephalopathies, could be originated by it. Newer agents (valproate, levetiracetam, or topiramate) might be an interesting option<sup>1</sup>. These drugs are also useful as antiepileptic drugs after SE. Levetiracetam was not available to us. We tried topiramate

and fortunately obtained a good response with a relatively low dosage. Then, we suggest topiramate for treatment of both, SE and seizures, in Sialidosis. Topiramate is possibly also a useful drug for other forms of progressive myoclonic epilepsies. Further studies are necessary to clarify these matters.

## REFERENCES

1. Bleck TP. Intensive care unit management of patients with status epilepticus. *Epilepsia* 2007;48(Suppl 8):S59-S60.
2. Costello DJ, Cole AJ. Treatment of acute seizures and status epilepticus. *J Intensive Care Med* 2007;22:319-347.
3. Gopaul KP, Crook MA. The inborn errors of sialic acid metabolism and their laboratory investigation. *Clin Lab* 2006;52:155-169.
4. Lowden JA, O'Brien JS. Sialidosis: a review of human neuraminidase deficiency. *Am J Hum Genet* 1979;31:1-18.
5. Pshzhetsky AV, Richard C, Michaud L, et al. Cloning expression and chromosomal mapping of lysosomal sialidase and characterization of mutations in sialidosis. *Nat Genet* 1997;15:316-320.

## TOPIRAMATO É EFETIVO NO TRATAMENTO DE ESTADO DE MAL EPI-LÉPTICO E CONTROLE DE CRISES NA DEFICIÊNCIA DE NEURAMINIDASE

<sup>1</sup>Division of Neurology, Hospital de Clínicas de Porto Alegre, Porto Alegre RS, Brazil; <sup>2</sup>Medical Genetics, Hospital de Clínicas de Porto Alegre, Porto Alegre RS, Brazil; <sup>3</sup>Division of Radiology, Hospital Moinhos de Vento, Porto Alegre RS, Brazil; <sup>4</sup>University of São Paulo School of Medicine, Neurology Department, São Paulo SP, Brazil; <sup>5</sup>Department of Genetics, Universidade Federal do Rio Grande do Sul, Porto Alegre RS, Brazil.

**Correspondence:** José Augusto Bragatti - Rua Ramiro Barcelos 2350 / sala 2040 - 90035-003 Porto Alegre RS - Brasil. E-mail: jabragatti@terra.com.br

**Support:** The authors receive financial support from FAPERGS, FIPE and CNPq. Dr. Bianchin and Dr Schwartz were further supported by CNPq (#305501/2007-0 and # 305147/2007-2, respectively).

Received 24 January 2011. Received in final form 18 February 2011. Accepted 3 March 2011.