

UNIVERSIDADE FEDERAL DO RIO GRANDE DO SUL

FACULDADE DE ODONTOLOGIA

PROGRAMA DE PÓS-GRADUAÇÃO EM  
ODONTOLOGIA

CAPACIDADE DIAGNÓSTICA DA  
RADIOGRAFIA CONVENCIONAL E DA  
TOMOGRAFIA COMPUTADORIZADA DE  
FEIXE CÔNICO PARA A AVALIAÇÃO DO  
CANAL MÉLIO-PALATINO EM MOLARES  
SUPERIORES

MARIANA BOESSIO VIZZOTTO

PORTO ALEGRE

2011

UNIVERSIDADE FEDERAL DO RIO GRANDE DO SUL  
FACULDADE DE ODONTOLOGIA  
PROGRAMA DE PÓS-GRADUAÇÃO EM ODONTOLOGIA

CAPACIDADE DIAGNÓSTICA DA RADIOGRAFIA CONVENCIONAL  
E DA TOMOGRAFIA COMPUTADORIZADA DE FEIXE CÔNICO  
PARA A DETECÇÃO DO CANAL MÉLIO-PALATINO EM MOLARES  
SUPERIORES

MARIANA BOESSIO VIZZOTTO

PORTO ALEGRE

2011

UNIVERSIDADE FEDERAL DO RIO GRANDE DO SUL  
FACULDADE DE ODONTOLOGIA  
PROGRAMA DE PÓS-GRADUAÇÃO EM ODONTOLOGIA

CAPACIDADE DIAGNÓSTICA DA RADIOGRAFIA CONVENCIONAL  
E DA TOMOGRAFIA COMPUTADORIZADA DE FEIXE CÔNICO  
PARA A DETECÇÃO DO CANAL MÉLIO-PALATINO EM MOLARES  
SUPERIORES

Linha de Pesquisa

Diagnóstico de Afecções Buco-Faciais

MARIANA BOESSIO VIZZOTTO

Orientadora: Prof. Dr<sup>a</sup>. HELOÍSA EMÍLIA DIAS DA SILVEIRA

Tese apresentada ao Programa de Pós-Graduação em Odontologia, da Universidade Federal do Rio Grande do Sul, como pré-requisito final para a obtenção do título de Doutor em Clínica Odontológica – ênfase em Radiologia.

Porto Alegre, 2011

*Faça o que puder, com o que tiver, onde estiver.*

*Theodore Roosevelt*

## Agradecimentos

---

A **Deus**, que por sua presença e força sempre me abençoa e capacita para tudo aquilo que me destina.

Aos meus pais, **Assis e Mariza**, pelo apoio e incentivo incondicionais. Aos meus queridos irmãos, **Bruno e Cassiano**, por sempre torcerem por mim.

Ao **Luciano**, por seu amor que me deixa mais forte para superar os desafios.

À minha orientadora, Prof<sup>a</sup> Dr<sup>a</sup> **Heloísa Emília Dias da Silveira**, que sempre demonstrou acreditar no meu potencial, pela oportunidade oferecida, pela orientação e principalmente pelo bom convívio nestes anos de trabalho.

Ao pessoal técnico do Laboratório de Endodontia da FOP-Unicamp, especialmente em nome da Prof<sup>a</sup> Dr<sup>a</sup> **Brenda Paula Figueiredo de Almeida Gomes**, que permitiu o uso dos equipamentos do seu laboratório indispensáveis à realização deste trabalho.

Ao Prof. Dr. **Fernando Borba de Araújo**, Prof. Dr. **Marcus Vinícius Reis Só** e Prof. Dr. **Heraldo Luís Dias da Silveira** que, como membros da banca de defesa do projeto e da banca de qualificação, contribuíram com importantes e enriquecedoras sugestões.

Ao Prof. Dr. **Reni Raimundo Dalla Bona** pelo exemplo de persistência, determinação e competência.

Ao Prof. Dr. **Francisco Montagner**, pelo carinho e prontidão com que sempre me auxiliou na parte prática, na análise dos resultados e na tradução desse trabalho.

Às colegas de doutorado, **Letícia** e **Nádia**, não só pela amizade, mas, principalmente, pelo sorriso e bom humor constantes.

Às colegas da Radiologia, **Priscila** pelo apoio irrestrito em todas as etapas desse trabalho, especialmente na jornada passada em Piracicaba. À **Gabriela** pelos anos de amizade e ao **Mathias** pela agradável convivência.

Aos alunos bolsistas de iniciação científica, **Fernanda**, **Átila**, **Manuela** e especialmente à **Lisângela**, pela ajuda na parte prática desse trabalho.

Às queridas amigas, **Geisa** e **Diana**, pelo carinho e amizade.

Ao **Hospital de Aeronáutica de Canoas**, especialmente às chefias da Divisão de Odontologia, que entenderam a minha vontade de realizar o projeto de pós-graduação, apoiando-me da melhor maneira possível para que eu me qualificasse profissionalmente.

A todos os **colegas do HACO**, pela convivência diária nesses cinco anos.

A todos os professores do **Curso de Odontologia da UFSM**, pelos ensinamentos prestados durante o curso de graduação e, em especial, a todos os **colegas da ATO 2004-1 UFSM** pela maravilhosa convivência.

A toda minha **família Boessio e Vizzotto**, pela insubstituível convivência ao longo da minha vida. À **família Casagrande**, que me acolheu como filha, muito obrigada.

À coordenação, professores e funcionários do **Programa de Pós-Graduação da FO-UFRGS**.

A todos que, direta ou indiretamente, contribuíram para a realização deste trabalho.

## Sumário

---

Lista de Abreviaturas e Siglas	07
Resumo	09
Abstract	11
Introdução	13
Objetivos	20
Artigo 1	21
Artigo 2	38
Considerações Finais	53
Referências	55
Anexo 1	60
Anexo 2	61

## Lista de Abreviaturas e Siglas

---

MP – méso-palatino

TCFC – tomografia computadorizada de feixe cônico

mm – milímetros

MV – méso-vestibular

MO – microscópio operatório

microTC – microtomografia computadorizada

MB2 – *second mesiobuccal canal* / canal méso-palatino

CBCT – *cone beam computed tomography* / tomografia computadorizada de feixe cônico

MB1 – *first mesiobuccal canal* / canal méso-vestibular

RE – *radiographic examination*

S1, S2, S3 – *stage 1, 2 and 3*

UFRGS – Universidade Federal do Rio Grande do Sul

UNIFRA – Centro Universitário Franciscano

mL – mililitro

s – segundos

° - graus

FOV – *field of view* / campo de visão

% – porcentagem

GL – *Gay-Lussac*



ANOVA – *Analysis of Variance* / Análise de Variância

v. – *version*

CT – *computed tomography* / tomografia computadorizada

kVp – kilovolt pico

mA – miliampere

cm – centímetro

CI – *confidence interval* / intervalo de confiança

vs – versus

CCD – *charged coupled device* / dispositivo de carga acoplada

PSP – *photostimulable phosphor plate* / placa de fósforo fotoestimulada

FO-UFRGS – Faculdade de Odontologia da Universidade Federal do Rio Grande do Sul

As dificuldades impostas pela anatomia do sistema de canais radiculares são causas freqüentes de falhas no tratamento endodôntico, principalmente no primeiro molar superior onde a prevalência do canal méso-palatino (MP) é variável. A condição clínica do dente e a presença de materiais restauradores ou obturadores parecem impor dificuldades para a detecção da presença do canal MP, especialmente quando métodos de imagem são utilizados. Assim, este estudo teve como objetivos: i) avaliar a capacidade diagnóstica da radiografia convencional e da tomografia computadorizada de feixe cônico (TCFC) com diferentes tamanhos de voxel na detecção do canal MP em diferentes situações radiculares; e, ii) avaliar a reprodutibilidade do diagnóstico do canal MP nas mesmas condições. Exames radiográficos e tomográficos (voxel 0.2-mm, 0.25-mm e 0.3-mm), de oitenta e nove molares superiores humanos extraídos foram realizados em três etapas: canal méso-vestibular (MV) vazio, obturado e após a desobturação. Em seguida, foi realizada a infiltração de corante e diafanização dos dentes. Para a análise estatística utilizou-se o software PASW Statistics 17.0. Para o primeiro objetivo, um examinador, cegado e calibrado, avaliou as imagens para a detecção do canal MP. Como resultados desse estudo pôde-se observar que a TCFC é um método complementar fidedigno para a investigação do canal MP. Em dentes com o canal MV obturado deve-se escolher o protocolo 0.2-mm, entretanto para canais radiculares sem preparo e sem obturação e canais desobturados, a escolha do tamanho de voxel 0.3-mm mostrou-se suficiente para um correto

diagnóstico. Para o segundo objetivo proposto, três examinadores, calibrados e cegados, avaliaram as imagens e diagnosticaram a presença ou ausência do canal MP. Na avaliação de reprodutibilidade de diagnóstico, pode-se concluir que a condição do canal foi o fator mais relevante para a variação nos resultados quando comparado ao tamanho do voxel e experiência do examinador. Esses resultados devem ser considerados quando existe a suspeita da presença de um canal MP em um dente onde o re-tratamento endodôntico for necessário, visto que a remoção do material antes da solicitação do exame por imagem reduz os artefatos permitindo a utilização de um protocolo com voxel 0.3-mm, que se mostrou capaz de permitir um correto diagnóstico com menor dose de exposição para o paciente.

**DESCRITORES:** diagnóstico, sistema de canais radiculares, radiografia convencional, tomografia computadorizada de feixe cônico.

The difficulties imposed by the anatomy of the root canal system are a frequent cause of endodontic treatment failures, especially in upper first molars where the prevalence of the second mesiobuccal canal (MB2) is variable. Several methods have been proposed to detect this root canal, but also is important to consider the influence of the clinical condition of the over tooth its the correct diagnosis. Therefore, this study was aimed: i) to assess the diagnostic ability of conventional radiography and CBCT with different voxel sizes in the detection of MB2 in different root conditions; and, ii) to assess the reproducibility of this diagnosis under the same conditions. Radiographs and CBCT scans (0.2-mm, 0.25-mm and 0.3-mm voxel) of eighty-nine extracted human molars were performed in three steps: first mesiobuccal canal (MB1) non filled, filled and after deobturation. Then, samples were cleared. Three examiners, calibrated and blinded, evaluated the images and pointed out the presence or absence of MB2. Statistical analysis was carried on with the PASW Statistics 17.0 software. It was observed that CBCT is a secure complementary method for investigating the presence of MB2. Moreover, when the MB1 canal is filled should be choose the 0.2-mm protocol. The 0.3-mm voxel size images proved to be adequate for a correct diagnosis when the MB1 was non filled or deobtured. In the assessment of diagnostic reproducibility, it can was concluded that the MB1 seemed to be a determinant factor for the result outcome canal condition when compared to the voxel size and the examiner's experience. These results should be considered when an endodontic re-treatment was indicated, specially when the presence of a MB2 is suspected.

The removal of endodontic material prior to request the images exams reduces the presence of artifacts, allowing the use of the 0.3-mm voxel protocol. It was able to allow a correct diagnosis with less patient exposure to the X ray.

**DESCRITORES:** diagnosis, endodontic canal system, conventional radiography, cone beam computed tomography.

O sucesso de um tratamento endodôntico depende do conhecimento da anatomia do sistema de canais radiculares. Habitualmente, os primeiros molares superiores possuem três raízes e três canais radiculares. Porém, estudos mostram grande variação na prevalência do quarto canal, de 18% a 96,1% [1-6], este localizado geralmente na raiz méso-vestibular (MV) e usualmente chamado de canal méso-palatino (MP).

Além da variação existente na prevalência, as diversas configurações que esse canal pode apresentar também influenciam no seu correto diagnóstico e tratamento. Com a finalidade de facilitar o entendimento desse complexo sistema de canais e universalizar o conhecimento, Weine *et al.* [7], em 1969, classificaram pela primeira vez o sistema de canais radiculares. Vertucci [8] desenvolveu mais tarde outra classificação, bastante utilizada até hoje, especialmente para o uso em estudos *in vitro*.

A existência do segundo canal na raiz MV dos molares superiores, especialmente o primeiro molar superior já foi tema de muitos estudos [2, 4-6, 9-11].

Pécora *et al.* [10] avaliaram a anatomia de 370 molares superiores e observaram que o primeiro, segundo e terceiro molares superiores apresentavam três canais em 75%, 58% e 68% dos dentes, respectivamente. Quatro canais foram encontrados em 25% dos primeiros, em 42% dos segundos e, 32% dos terceiros molares superiores. O quarto canal foi encontrado principalmente na raiz MV desses dentes.

Além da presença do 4º canal, o istmo é outra peculiaridade anatômica que muitas vezes se faz presente na raiz MV do primeiro molar superior. O istmo é definido como uma passagem que liga dois ou mais canais na mesma raiz. A incidência do istmo na raiz MV de molares superiores varia de 4,9% até 52%; e quando o istmo parcial é incluído, a incidência é de 100% nas raízes com canais múltiplos nos molares superiores [12-14].

Iqbal & Fillmore [15], com estudo de banco de dados, verificaram que a idade do paciente foi fator importante na detecção de menor quantidade de canais em molares superiores. Isto se deve, possivelmente, às mudanças morfológicas de calcificação que ocorrem com a idade. Essa pode ser uma das razões das discrepâncias no número de canais méso-palatinos detectados nos diferentes estudos. Ainda, Corcoran *et al.* [16] afirmaram que a experiência e conhecimento do cirurgião-dentista tem um efeito positivo e grande impacto sobre o número de canais localizados e preenchidos em molares superiores.

Hess & Zurcher [17] já mostravam, em 1925, as conseqüências de não diagnosticar o canal MP no tratamento endodôntico. Weine *et al.* [7] constataram que, especificamente no primeiro molar superior, a maior quantidade de falha de obturação se dá no MP, possivelmente pela incapacidade de se localizar e sanificar esse conduto adequadamente.

Determinar qual o melhor método para se localizar o canal MP tem sido assunto de interesse de vários autores [14, 18-22].

A diafanização é uma técnica utilizada para o estudo da anatomia interna dos dentes. Este método compreende a injeção de tinta nanquim no

interior dos canais e, posteriormente, descalcificação de toda estrutura de tecido duro do dente de modo que a mesma se torne translúcida [8]. A diafanização e os cortes seriados são métodos possíveis somente *in vitro*.

Clinicamente, várias ferramentas têm sido incorporadas aos procedimentos endodônticos tem como objetivo superar as dificuldades impostas pela anatomia interna do sistema de canais radiculares [1, 19, 23, 24]. Dentre elas, destaca-se a magnificação, representada clinicamente pelo uso de lupa e microscópio operatório (MO). Nos Estados Unidos, a Associação Dental Americana recomenda a utilização de MO em curso de residência em Endodontia, sendo este um dos pré-requisitos essenciais para o credenciamento da instituição nos exames de título de especialistas [25]. Os benefícios do emprego do MO em diferentes situações clínicas se devem também à iluminação direta do campo operatório. A visualização detalhada das particularidades anatômicas do sistema de canais radiculares permite um exame clínico minucioso e também um tratamento mais adequado [19, 26, 27].

Várias pesquisas têm apontado a vantagem do microscópio sobre o uso de outros instrumentos que empregam magnificação. Quando comparado com lupas de aumento, o microscópio ou foi comparável ou superior para o diagnóstico do sistema de canais radiculares [14, 18, 27, 28]. De acordo com o estudo *in vitro* de Gorduysus *et al.* [28], os observadores detectaram 93% dos segundos canais na raiz MV sem auxílio do microscópio e 96% com auxílio, porém o desempenho na instrumentação dos canais melhorou em 11% quando comparado com a não ampliação.



Em um estudo *in vivo*, Sempira & Hartwel [18], puderam concluir que o MO mostrou um incremento de 30% na localização do segundo canal na raiz MV. Buhley *et al.* [23] observaram um incremento de até 71% na localização do canal MP quando da utilização de lupa ou microscópio operatório, demonstrando ser esta uma importante ferramenta para o uso clínico em Endodontia.

No campo de diagnóstico através da imagem, o método radiográfico é o mais utilizado para a observação da quantidade de raízes e canais radiculares. Entretanto, um estudo realizado por Omer *et al.* [22], onde os autores avaliaram radiografias vestibulo-linguais e méso-distais de molares superiores para avaliar a detecção do canal MP, este exame mostrou baixos valores de concordância, demonstrando a dificuldade da observação de estruturas tridimensionais em apenas duas dimensões.

O desenvolvimento da tomografia computadorizada de feixe cônico (TCFC), inicialmente mais utilizada para planejamento em implantodontia, difundiu a utilização das imagens tomográficas nas mais diversas áreas da Odontologia. Do ponto de vista endodôntico, muitas aplicações têm sido utilizadas, como: análise de reabsorções externas [29-31] e internas, diagnóstico de fraturas radiculares, planejamento pré-operatório e estudo da morfologia dos canais radiculares [32-34]. A capacidade da TCFC em confirmar condições patológicas e estruturas anatômicas em reconstruções tridimensionais tem se mostrado extremamente útil. A característica de reduzir ou eliminar sobreposições mostra a superioridade desse tipo de exame para o correto diagnóstico de diversas condições clínicas em Endodontia.

A TCFC é um exame baseado na tomografia volumétrica, onde os dados são adquiridos a partir de uma única volta da fonte de raios X ao redor da cabeça do paciente, gerando uma imagem em três dimensões, em escala de 1:1 com a imagem real [35-38]. A TCFC apresenta algumas vantagens específicas para o uso odontológico, tais como: natureza isotrópica do voxel; rapidez para a realização do exame (até 70 segundos); baixa dose de radiação a que o paciente é submetido quando comparada à tomografia de feixe em leque; menor interferência na imagem produzida por artefatos metálicos [39]; acesso facilitado para a rotina odontológica (uma vez que o aparelho é compacto) e redução de custos [38, 40].

As aplicações da TCFC na caracterização do sistema de canais radiculares foram reportadas inicialmente por Tachibana & Matsumoto [41], onde foi realizada análise da morfologia do canal. Baratto *et al.* [24] utilizaram três métodos (*ex vivo*, clínico e TCFC) para avaliar a morfologia interna dos primeiros molares, e concluíram que a TCFC foi eficaz para a identificação inicial de tal morfologia.

Blattner *et al.* [42] avaliaram 20 dentes, com objetivo de estudar a acurácia do exame de TCFC em diagnosticar a presença ou não do canal MP em primeiros molares superiores. Para isso, os autores avaliaram exames de TCFC e cortes seccionais. Os cortes mostraram 68,4% de presença do canal MP e o diagnóstico com a TCFC apontou valores de 57,9%. Além disso, a concordância intra-examinador foi de 90%, demonstrando este ser um exame reproduzível e sem diferença estatística frente aos cortes seccionais.

Em relação à presença de artefatos metálicos, com prejuízo para a avaliação das imagens, os estudos apresentam resultados inconclusivos. Para o diagnóstico de cárie proximal, Sanders *et al.* [43] observaram que a presença de braquetes ortodônticos metálicos afetou a qualidade da imagem, prejudicando o correto diagnóstico desse tipo de lesão. Alguns autores citam que o exame por tomografia apresenta altos valores de sensibilidade e especificidade, porém a presença de artefatos ainda é uma limitação que pode afetar o diagnóstico [34, 44].

Nos últimos anos, o desenvolvimento da microtomografia (microTC) tem ganho crescente importância na Odontologia. A microTC é uma técnica não-invasiva de avaliação tridimensional dos sistemas de canais radiculares e que pode ser aplicada tanto de maneira quantitativa como qualitativa. Além disso, a anatomia interna e externa dos dentes pode ser demonstrada simultaneamente ou separadamente. Entretanto, esta técnica não pode ser executada clinicamente. Mesmo em estudos *in vitro*, a microTC apresenta algumas desvantagens como o alto custo e o tempo de escaneamento consideravelmente longo. [21, 45, 46]

Conforme citam as diretrizes para utilização da TCFC em Odontologia ("*Evidence Based Guidelines 2011 - Radiation protection: cone beam CT for dental and maxillofacial radiology*") [47], alguns estudos sugerem que a TCFC oferece grande qualidade de imagem, o que faz com que ela seja um exame com boas perspectivas. Porém, para o diagnóstico endodôntico é necessário um alto grau de detalhamento, fator muito importante a ser discutido, visto que o exame de TCFC oferece uma resolução bem mais baixa do que muitas

radiografias intrabucais modernas. Além disso, especificamente para Endodontia, o volume de área (campos de visão) que os aparelhos de TCFC possuem não são suficientemente restritos, o que acaba fazendo com que o paciente seja exposto à radiação X em áreas excessivas, sem benefício algum. Os autores concluem que mais pesquisas devem ser realizadas para se estabelecer objetivamente a acurácia TCFC para o diagnóstico do sistema de canais radiculares e também o quanto esse exame gera de impacto para a decisão clínica. [32, 34, 38, 47]

Por fim, considerando a complexidade anatômica do sistema de canais radiculares presente nos primeiros molares superiores e a necessidade de realização de exame por TCFC para sua avaliação, justifica-se a realização de um estudo que compare a capacidade diagnóstica da radiografia convencional e da TCFC para a detecção da presença ou ausência do canal méso-palatino, com diferentes protocolos de voxel em diferentes condições clínicas. Além disso, se torna importante a avaliação da reprodutibilidade do diagnóstico desse exame por diferentes observadores, permitindo assim, uma análise crítica da TCFC para a avaliação do sistema de canais radiculares.

### Geral

Realizar estudo para avaliar diferentes métodos de imagem, radiografia convencional e TCFC, para a detecção e reprodutibilidade do correto diagnóstico do canal MP em três diferentes condições de preenchimento do canal méso-vestibular.

### Específicos

- i. Avaliar a capacidade diagnóstica da radiografia convencional e da tomografia computadorizada de feixe cônico com diferentes tamanhos de voxel, para a detecção do canal méso-palatino em diferentes condições de preenchimento do canal méso-vestibular;
- ii. Avaliar a reprodutibilidade de diferentes observadores para o diagnóstico do canal méso-palatino com a utilização da tomografia computadorizada de feixe cônico, com diferentes tamanhos de voxel, em diferentes condições de preenchimento do canal méso-vestibular.

CBCT for assessment of mesiobuccal second (MB2) canal: performance of voxel sizes in different root conditions.

*Mariana Boessio Vizzotto*

*Priscila Fernanda da Silveira*

*Nádia Assein Arús*

*Francisco Montagner*

*Brenda Paula Figueiredo de Almeida Gomes*

*Heloísa Emília Dias da Silveira*

## **ABSTRACT**

**Objectives:** this study aimed compares the detection of the MB2 using the different voxel sizes of the CBCT and conventional radiographic imaging in different root conditions. **Methods:** Eighty-nine extracted human first upper molars were selected for the study. The RE and 0.2-mm, 0.25mm and 0.3mm CBCT was take in three stages: (S1) – no MB1 root canal preparation and filling; (S2) – after MB1 preparation and filling; and, (S3) – after the MB1 root canal filling removal and reparation. The images were analyzed by a blinded, previously calibrated examiner. The mean values for accuracy, specificity and sensitivity were used in proportion and compared by Analysis of Variance. Statistical analysis was carried out by the software SPSS for Windows. **Results:** The results show that in samples with canal filling (S2), the 0.2-mm

voxel size could be a good choice and in teeth with non filled MB1 (S1) or deobturated (S3) a 0.3-mm voxel size protocol can be employed because its associate great accuracy results for MB2 diagnosis with lower patient exposition.

## **INTRODUCTION**

The root canal system morphology has been a complex and extremely important issue regarding the planning and execution of endodontic therapy. The several anatomic variations that might exist in the root canal system have contributed to endodontic treatment failures. Maxillary first molars have frequently 3 roots and 3 or 4 canals (1). In fact, it has been suggested that the variation of the presence of a second mesiobuccal canal (MB2) ranges from 18% to 96.1% in upper molars (2-7). Weine et al. (8) have remarked specifically that the failure of endodontic treatment of permanent maxillary first molars is likely caused by the failure to find and obturate the MB2 canal. Revealing the location of the MB2 canal has proven to be the most formidable component of adequately treating these canals because it clearly must be done before cleaning, shaping, and obturation.

Several researches have suggested different bench and clinical methods to best detect the MB2 (9-15). Adjunctive tools, such as magnifying loupes and dental operating microscopes, orthogonal and dissociates radiographs are commonly used to increase the detection of MB2 canals (15-19). However, these instruments seem not to be enough to allow the location of the MB2 canals in all clinical situations.

Cone-beam computed tomography (CBCT) has been largely employed in several areas of dental clinics and research. The ability of CBCT in Endodontics have been reported by several authors for the diagnosis of the internal anatomy (20), apical lesions (14), root resorption (21), root fractures (22). Despite the advantages provided by the CBCT technology, there are some limitations. The presence of streaking artifacts can compromise the quality of the scan (23). In Endodontics, specific materials such as gutta-percha and intracanal metallic post may contribute to artifacts formation (22, 24).

Therefore, this study compared the ability of CBCT with different voxel sizes and conventional radiographic imaging in different root situations in the detection of the MB2.

## **MATERIAL AND METHODS**

### **Study design**

The present study was approved by the Ethics Committee in Research from the Federal University of Rio Grande do Sul (UFRGS, Porto Alegre, Rio Grande do Sul, Brazil). Eighty-nine extracted human first upper molars were selected for the study. They were donated by the Human Teeth Bank of Franciscan University (UNIFRA, Santa Maria, Rio Grande do Sul, Brazil).

The presence of the MB2 in the MB root from maxillary upper first molars was assessed in three different stages, as follows:

- Stage 1 (S1) – no MB1 root canal preparation and filling;



- Stage 2 (S2) – after MB1 preparation and filling; and,
- Stage 3 (S3) – after the MB1 root canal filling removal and repreparation.

### **Procedures for root canal preparation, filling and deobturation**

For MB1 preparation, the coronal access was previously performed cutting the teeth crown. The MB1 root canal patency was determined when the #10 K-file reached the apical foramen, as detected under direct visualization. The working length was set 1mm shorter than the length where the initial file was visualized at the apical foramen. The MB1 was initially instrumented up to a #20 K-file. Cervical and middle thirds were flared with a #2 Largo drill, followed by Gates Gliden drills (#4, #3 and #2 respectively) with a pressure less movement. The specimens were then instrumented with ProTaper rotary files (Dentsply/Maillefer, Ballaigues, Orbe, Switzerland) up to size F3 as the apical master file, according to the manufacturer. Irrigation was performed with 3mL of saline at each file change. Then, the MB1 was filled with 17% EDTA during 3 minutes, flushed with saline, dried with absorbent paper points, and obturated by the lateral compaction of gutta-percha cones and zinc oxide and eugenol-based cement (Endofill; DentsplyInd Com Ltda, Petrópolis, RJ, Brazil).

Root canal filling was removed without solvent using the D1, D2 and D3 ProTaper retreatment instruments (Dentsply/Maillefer, Ballaigues, Orbe, Switzerland) as previously described by Bramante *et al.* (25). Instruments were

used with a brushing motion against the canal walls in a crown-down direction until reaching the working length. D1 worked in the cervical third, D2 in the middle third, and D3 in the entire working length, according to the manufacturer's instructions.

### **Assessing the presence of the MB2**

Samples were analyzed in S1, S2 and S3 through conventional radiographic examination (RE) and cone beam computed tomography (CBCT). All teeth were standardly radiographed (Kodak, Dental Intraoral D-Speed Film; size 2; 0.4 s) with three different horizontal angles, based on the buccal surface: orthogonal (0°), mesial and distal angulation (15°) (27). To prepare the samples and simulate a clinical situation each teeth was covered by a layer of wax, simulating the soft tissues, and a block of bone to simulate the maxilla and processed by automatic machine. The film images were evaluated under transmitted light from a radiographic view box under magnification. The ambient light of the film was removed by mask. For the tomographic acquisition, all samples were put together and placed on the desk of the i-CAT tomography device (Imaging Sciences International, Inc, Hatfield, PA, USA; 120 kVp, 3-8 mA). Axial, frontal, and sagittal sections were obtained with specific protocols based on the voxel resolution: 0.3-mm voxel (8-cm field of view [FOV], 20 seconds for acquisition), 0.25-mm voxel (8-cm FOV, 40 seconds for acquisition), and 0.2-mm voxel (8-cm FOV, 40 seconds for acquisition). Images were analyzed using the i-CAT Vision software (Imaging Sciences International Inc, Hatfield, PA, USA).

After RE and CBCT acquisition in S3, all samples were clarified to directly visualize the presence of MB2. The external surface of each sample was covered with three layers of nail varnish, except the 3 mm region surrounding the apex of the tooth. Then the pulp chamber was filled with Indian ink (Royal Talens, Apeldoorn, Netherlands) and inserted in a vacuum chamber for 6 hours. Then, the excess of dye was removed by washing in tap water for a 6-hour period. For clearing procedures, the nails varnish was removed with a blade. Samples were immersed in 5% hydrochloric acid for 12 hours; washed in tap water (4 hours); dehydrated in an ascending alcohol battery (75GL, 85GL, 95GL, 100GL) (3 hours each); and immersed in methyl salicylate for clarification. During the process of clearing nine samples were missed.

The configuration of the MB1 and MB2 in the mesiobuccal root was recorded through photographic imaging in a stereomicroscope (Leica Microsystems, Wetzlar, Germany). These images were considered the gold standard for RE and CBCT comparisons.

### **RE/CBCT imaging data and statistical analysis**

The RE and CBCT images were analyzed by a blinded, previously calibrated examiner. The previous calibration consisted on the identification of the existence of MB2 in 20 radiographs and tomograms that did not belong to the study sample. At a 15-day interval, the same observation was repeated. Results at the two time periods were evaluated using Kappa statistics to check intra-observer reproducibility. The values obtained for Kappa were  $> 0.70$ .

Diagnostic ability for both radiographic and tomographic method (considering voxel resolution) was measured by accuracy, specificity and sensitivity findings. In the fields of science and statistics accuracy of an object is a measure of how closely the experimental results agree with a true or accepted value. Accuracy can be expressed through sensitivity and specificity, positive and negative predictive values, or positive and negative diagnostic likelihood ratios. The sensitivity of a test is the probability that it will produce a true positive result when the samples have the event (as compared to a reference or "gold standard"). The specificity of a test is the probability that a test will produce a true negative result when the samples don't have the event (as determined by a reference or "gold standard").

The mean values for accuracy, specificity and sensitivity were used in proportion and compared by Analysis of Variance (ANOVA). Statistical analysis was carried out by the software PASW v.19.0 for Windows (SPSS, Chicago, IL, USA).

## RESULTS

The MB2 root canal was detected in 67.1% of the samples through the clearing technique.

The mean values for MB2 detection regarding the diagnostic method are shown in **Table 1**. RE revealed a low frequency for the detection of MB2 than CBCT analysis, regardless the MB1 condition. A greater detection of MB2 was observed for the non filled MB1 followed by deobturated MB1 for 0.3mm-voxel

images. The root canal condition did not influence the detection of the MB2 in the 0.2mm-voxel images. The presence of root canal filling in MB1 reduced the detection of MB2 especially for 0.3-mm and 0.25-mm voxel sized images.

**Table 2** shows the detection rate for the MB2, regarding the MB1 condition. There was no difference for MB2 detection with CBCT when the MB1 had received no treatment (S1 samples). However, 0.2mm and 0.25mm voxel-sized images provided best MB2 detection rates when the MB1 was filled (S2). In the S3 condition, great detection rates for MB2 were observed for both 0.2mm and 0.3mm voxel sized images than for 0.25-mm voxel-size images in the CBCT.

**Table 3** show the mean values of sensitivity and specificity for RE and CBCT methods. The ability of RE to detect MB2 when it is present in the sample is lower than for CBCT, demonstrating low values for the sensitivity test. 0.3-mm voxel-size images provided low detection rates for filled MB1 root canals (S2). For the 0.25-mm the specificity values decreased for the deobturated MB1. The MB1 condition did not compromise the MB2 detection in 0.2-mm voxel-size images, especially in sensitivity test. The ability to demonstrate the absence of MB2 when it is not in the sample was inferior in 0.3-mm voxel-size images. There was no difference in the mean specificity values for MB2 in both 0.2-mm and 0.25-mm voxel-size images, despite MB1 condition.

## **DISCUSSION**

The prevalence of additional root canals has been reported and discussed by several authors. In clinical situations where the presence of MB2 is suspected, its early detection is a key to a successful root canal treatment. This study aimed to compare the ability of conventional RE and CBCT scans with different voxel sizes to detect the presence of the MB2, in different MB1 conditions, in order to identify the best relationship between image quality and reduced patient exposure to radiation.

The clearing technique is frequently used as the gold standard. It comprises the injection of India ink inside the canals system followed by the decalcification of the hard structure and clearing. The sample becomes translucent and the root canal system can be directly visualized (26). Even possessing high accuracy values, it is an *in vitro* technique that did not allow the sample recovery for further analysis. A great variety of methods such as radiographs, magnification and direct clinical evaluations have been used to describe the MB2 anatomy (2, 15, 18, 27-29). Recently, CBCT examination was introduced in Dentistry and has been widely employed for oral diagnosis (30). CBCT seems to improve the diagnostic ability of MB2 because it allows visualizing the image from multiple orientations at very thin slices without disturbance of overlapping of structures (30). The presence of streaking artifacts can compromise the quality of the scan (24, 31). Although it is known that CBCT provides more accurate imaging information about the diagnosis of endodontic diseases and conditions, there is little evidence on the influence of the root canal filling and the voxel size in the detection of MB2 (18, 27, 32).

For the CBCT, the dose of radiation depends on the voxel resolution because of the exposure time. The small voxel size requires more number of acquisitions, increasing the patient's radiation exposure (33). In this study, the i-Cat tomography acquisitions used had a scanning time of twenty seconds for the 0.3-mm and forty seconds for the 0.25-mm and 0.2-mm voxel sizes. The results show that in samples with non filled MB1 (S1) and deobturated (S3), the diagnostic ability of CBCT was similar for all tested voxel (0.3-mm, 0.25-mm and 0.2-mm). Therefore, in these root conditions, a 0.3-mm voxel size protocol can be employed because its associate great accuracy results for MB2 diagnosis with lower patient exposition (34).

Some authors report that the CBCT has high values of sensitivity and specificity in the diagnosis of MB2, however the presence of artifacts can be a limitation that may affect the analysis (11, 14, 35). In the present study, the influence of root canal filling materials was dependent on the CBCT voxel-size during examination. The accuracy of 0.2-mm voxel-size images to detect MB2 in filled MB1 root canals was greater than the other protocols, but without statistical difference with 0.25-mm voxel. Then, the reason for indication of the 0.2-mm voxel in the filling canals was based on the fact that even though the 0.25-mm voxel size CBCT provides fast image reconstruction, the dose of patient exposure is the same for both voxel sizes. Also, the results showed that although didn't have significant difference, the accuracy values decreased. Therefore, the patient care and the quality of the images is a priority for the excellence in diagnosis and treatment.

Radiographic examination had high specificity values. As reported, specificity means the ability of a specific test to detect the absence of the MB2 when it is not present in the sample. This finding is justified by the difficulty to determine the presence of MB2 because RE provides a two-dimensional image, causing a large number of false-negatives, which can be proven by the lower values of sensitivity. A previous study has shown that conventional radiographs fail to efficiently diagnose MB2 (15). Additional resources such as radiographic dissociation seemed not to improve the detection rate of MB2. Although the sensitivity scores were better than specificity, the results in this study showed that the CBCT examination provided great sensitivity and specificity values in the detection of MB2.

CBCT is a reasonable method to investigate the presence of MB2 after clinical examination. The results showed that for teeth with canal filling the 0.2-mm voxel size could be a good choice and when there is no filling material in the MB1, initial and deobturated teeth, the 0.3-mm voxel should be used. These findings must be considered when endodontic re-treatment was necessary because the filling removal before the CBCT exam eliminates the artifacts permitting the use of the 0.3-mm voxel protocol that are able to provide a great diagnostic performance with lower x-rays exposure to patient.



**Table 1.** Mean values of accuracy for each root situation, regarding the diagnostic method.

	MB1 no filled	MB1 filled	MB1 deobturated
	Mean ( $\pm$ EP)	Mean ( $\pm$ EP)	Mean ( $\pm$ EP)
RE	0.54 (0.06) <sup>a</sup>	0.45 (0.06) <sup>a</sup>	0.50 (0.06) <sup>a</sup>
0.3-mm voxel	0.87 (0.04) <sup>a</sup>	0.61 (0.06) <sup>c</sup>	0.74 (0.05) <sup>b</sup>
0.25-mm voxel	0.82 (0.04) <sup>a</sup>	0.69 (0.05) <sup>ab</sup>	0.63 (0.05) <sup>b</sup>
0.2-mm voxel	0.88 (0.04) <sup>a</sup>	0.81 (0.04) <sup>a</sup>	0.84 (0.04) <sup>a</sup>

Means followed by different uppercase letters in one same line indicate statistically significant difference for randomized block design ANOVA, complemented by the Tukey Test (5% significance level).

**Table 2.** Mean values of accuracy for each diagnostic method, regarding the root condition.

	RE	0.3-mm voxel	0.25-mm voxel	0.2-mm voxel
	Mean ( $\pm$ EP)	Mean ( $\pm$ EP)	Mean ( $\pm$ EP)	Mean ( $\pm$ EP)
MB1 no filled	0.54 (0.06) <sup>b</sup>	0.87 (0.04) <sup>a</sup>	0.82 (0.04) <sup>a</sup>	0.88 (0.04) <sup>a</sup>
MB1 filled	0.45 (0.06) <sup>c</sup>	0.61 (0.06) <sup>bc</sup>	0.69 (0.05) <sup>ab</sup>	0.81 (0.04) <sup>a</sup>
MB1 deobturated	0.50 (0.06) <sup>c</sup>	0.74 (0.05) <sup>ab</sup>	0.63 (0.05) <sup>cb</sup>	0.84 (0.04) <sup>a</sup>

Means followed by different uppercase letters in one same line indicate statistically significant difference for randomized block design ANOVA, complemented by the Tukey Test (5% significance level).

**Table 3.** Mean values of sensitivity and specificity for each group, regarding the diagnostic method.

	MB1 no filled		MB1 filled		MB1 deobturated	
	Sensitivity	Specificity	Sensitivity	Specificity	Sensitivity	Specificity
	Mean ( $\pm$ EP)	Mean ( $\pm$ EP)	Mean ( $\pm$ EP)	Mean ( $\pm$ EP)	Mean ( $\pm$ EP)	Mean ( $\pm$ EP)
RE	0.38 (0.07)	0.85 (0.03)	0.29 (0.06)	0.78 (0.08)	0.36 (0.07)	0.78 (0.08)
0.3-mm voxel	0.95 (0.03)	0.70 (0.09)	0.70 (0.06)	0.40 (0.10)	0.85 (0.05)	0.50 (0.10)
0.25-mm voxel	0.84 (0.05)	0.78 (0.08)	0.67 (0.06)	0.73 (0.09)	0.57 (0.07)	0.73 (0.09)
0.2-mm voxel	0.96 (0.03)	0.70 (0.09)	0.87 (0.05)	0.68 (0.09)	0.93 (0.04)	0.67 (0.09)

## REFERENCES

1. Pecora JD, Woelfel JB, Sousa Neto MD, Issa EP. Morphologic study of the maxillary molars. Part II: Internal anatomy. *Braz Dent J* 1992;3(1):53-57.
2. Hartwell G, Appelstein CM, Lyons WW, Guzek ME. The incidence of four canals in maxillary first molars: a clinical determination. *J Am Dent Assoc* 2007;138(10):1344-1346.
3. Kulild JC, Peters DD. Incidence and configuration of canal systems in the mesiobuccal root of maxillary first and second molars. *J Endod* 1990;16(7):311-317.
4. Weng XL, Yu SB, Zhao SL, Wang HG, Mu T, Tang RY, et al. Root canal morphology of permanent maxillary teeth in the Han nationality in Chinese Guanzhong area: a new modified root canal staining technique. *J Endod* 2009;35(5):651-656.
5. Pattanshetti N, Gaidhane M, Al Kandari AM. Root and canal morphology of the mesiobuccal and distal roots of permanent first molars in a Kuwait population--a clinical study. *Int Endod J* 2008;41(9):755-762.
6. Cleghorn BM, Christie WH, Dong CC. Root and root canal morphology of the human permanent maxillary first molar: a literature review. *J Endod* 2006;32(9):813-821.
7. Alavi AM, Opananon A, Ng YL, Gulabivala K. Root and canal morphology of Thai maxillary molars. *Int Endod J* 2002;35(5):478-485.
8. Weine FS, Healey HJ, Gerstein H, Evanson L. Canal configuration in the mesiobuccal root of the maxillary first molar and its endodontic significance. *Oral Surg Oral Med Oral Pathol* 1969;28(3):419-425.
9. Sempira HN, Hartwell GR. Frequency of second mesiobuccal canals in maxillary molars as determined by use of an operating microscope: a clinical study. *J Endod* 2000;26(11):673-674.

10. Kim S. Modern endodontic practice: instruments and techniques. *Dent Clin North Am* 2004;48(1):1-9.
11. Patel S, Dawood A, Whaites E, Pitt Ford T. New dimensions in endodontic imaging: part 1. Conventional and alternative radiographic systems. *Int Endod J* 2009;42(6):447-462.
12. Plotino G, Grande NM, Pecci R, Bedini R, Pameijer CH, Somma F. Three-dimensional imaging using microcomputed tomography for studying tooth macromorphology. *J Am Dent Assoc* 2006;137(11):1555-1561.
13. Stropko JJ. Canal morphology of maxillary molars: clinical observations of canal configurations. *J Endod* 1999;25(6):446-450.
14. Patel S, Dawood A, Ford TP, Whaites E. The potential applications of cone beam computed tomography in the management of endodontic problems. *Int Endod J* 2007;40(10):818-830.
15. Omer OE, Al Shalabi RM, Jennings M, Glennon J, Claffey NM. A comparison between clearing and radiographic techniques in the study of the root-canal anatomy of maxillary first and second molars. *Int Endod J* 2004;37(5):291-296.
16. Kim S, Baek S. The microscope and endodontics. *Dent Clin North Am* 2004;48(1):11-18.
17. Buhrlay LJ, Barrows MJ, BeGole EA, Wenckus CS. Effect of magnification on locating the MB2 canal in maxillary molars. *J Endod* 2002;28(4):324-327.
18. Baratto Filho F, Zaitter S, Haragushiku GA, de Campos EA, Abuabara A, Correr GM. Analysis of the internal anatomy of maxillary first molars by using different methods. *J Endod* 2009;35(3):337-342.
19. Pineda F, Kuttler Y. Mesiodistal and buccolingual roentgenographic investigation of 7,275 root canals. *Oral Surg Oral Med Oral Pathol* 1972;33(1):101-110.

20. Tachibana H, Matsumoto K. Applicability of X-ray computerized tomography in endodontics. *Endod Dent Traumatol* 1990;6(1):16-20.
21. Liedke GS, da Silveira HE, da Silveira HL, Dutra V, de Figueiredo JA. Influence of voxel size in the diagnostic ability of cone beam tomography to evaluate simulated external root resorption. *J Endod* 2009;35(2):233-235.
22. Melo SL, Bortoluzzi EA, Abreu M, Jr., Correa LR, Correa M. Diagnostic ability of a cone-beam computed tomography scan to assess longitudinal root fractures in prosthetically treated teeth. *J Endod* 2010;36(11):1879-1882.
23. Katsumata A, Hirukawa A, Okumura S, Naitoh M, Fujishita M, Aiji E, et al. Effects of image artifacts on gray-value density in limited-volume cone-beam computerized tomography. *Oral Surg Oral Med Oral Pathol Oral Radiol Endod* 2007;104(6):829-836.
24. Huybrechts B, Bud M, Bergmans L, Lambrechts P, Jacobs R. Void detection in root fillings using intraoral analogue, intraoral digital and cone beam CT images. *Int Endod J* 2009;42(8):675-685.
25. Bramante CM, Fidelis NS, Assumpcao TS, Bernardineli N, Garcia RB, Bramante AS, et al. Heat release, time required, and cleaning ability of MTwo R and ProTaper universal retreatment systems in the removal of filling material. *J Endod*;36(11):1870-1873.
26. Vertucci FJ. Root canal anatomy of the human permanent teeth. *Oral Surg Oral Med Oral Pathol* 1984;58(5):589-599.
27. Blattner TC, George N, Lee CC, Kumar V, Yelton CD. Efficacy of cone-beam computed tomography as a modality to accurately identify the presence of second mesiobuccal canals in maxillary first and second molars: a pilot study. *J Endod* 2010;36(5):867-870.
28. Corcoran J, Apicella MJ, Mines P. The effect of operator experience in locating additional canals in maxillary molars. *J Endod* 2007;33(1):15-17.
29. Saunders WP, Saunders EM. Conventional endodontics and the operating microscope. *Dent Clin North Am* 1997;41(3):415-428.

30. Scarfe WC, Farman AG, Sukovic P. Clinical applications of cone-beam computed tomography in dental practice. *J Can Dent Assoc* 2006;72(1):75-80.
31. Moura MS, Guedes OA, De Alencar AH, Azevedo BC, Estrela C. Influence of length of root canal obturation on apical periodontitis detected by periapical radiography and cone beam computed tomography. *J Endod* 2009;35(6):805-809.
32. Mozzo P, Procacci C, Tacconi A, Martini PT, Andreis IA. A new volumetric CT machine for dental imaging based on the cone-beam technique: preliminary results. *Eur Radiol* 1998;8(9):1558-1564.
33. Kim S, Song H, Samei E, Yin FF, Yoshizumi TT. Computed tomography dose index and dose length product for cone-beam CT: Monte Carlo simulations. *J Appl Clin Med Phys* 2011;12(2):3395.
34. Scarfe WC. "All that glitters is not gold": standards for cone-beam computerized tomographic imaging. *Oral Surg Oral Med Oral Pathol Oral Radiol Endod*;111(4):402-408.
35. Sanders MA, Hoyjberg C, Chu CB, Leggitt VL, Kim JS. Common orthodontic appliances cause artifacts that degrade the diagnostic quality of CBCT images. *J Calif Dent Assoc* 2007;35(12):850-857.

MB1 root condition influences both the MB2 diagnosis and CBCT diagnosis reproducibility

*Mariana Boessio Vizzotto*

*Priscila Fernanda da Silveira*

*Nádia Assein Arús*

*Gabriela Salatino Liedke*

*Francisco Montagner*

*Heraldo Luís Dias da Silveira*

*Heloísa Emília Dias da Silveira*

**Objectives:** The validity of any test of diagnosis depends on their reproducibility. The purpose of this study was to evaluate cone beam CT (CBCT) on the identification of mesiobuccal second root canal (MB2) considering different voxel sizes and mesiobuccal first root canal (MB1) filled condition. **Methods:** Three trained and calibrated post-graduate students in oral radiology were asked to identify the MB2 in eighty-two extracted human first upper molars in different condition depending on the MB1 root canal (without filling, filled and deobturated). Kappa value among the observers was obtained. **Results:** There was a reduction in the reproducibility values for non-filled, deobturated and filled MB1, respectively. **Conclusions:** The results suggest

that a root condition has more influence on identification of MB2 than the voxel size.

## **INTRODUCTION**

Cone-beam computed tomography (CBCT) imaging is based on a cone-shaped beam instead of the fan-shaped one used by regular computed tomography (CT) scanners. Cotton *et al.*<sup>1</sup> reported on the wide range of possibilities for the use of CBCT in Endodontics. They include the assessment of endodontic pathologies, internal and external resorption analysis, presurgical planning, pathologies of endodontic origin<sup>2</sup>, and canal morphology.<sup>3-6</sup> The ability of CBCT scans to observe pathologic conditions and anatomic structures in a three-dimensional reconstruction has proven to be incredibly useful. Their ability to reduce or eliminate superimposition of surrounding structures makes CBCT superior to conventional periapical films.<sup>5, 7, 8</sup>

The possibility to depict the presence of a complex root canal system has proved to be the most important way to properly assess these root canals before cleaning, shaping, and filling. The detection of the MB2 in first upper molar can be a hard task during clinical procedures. Additionally, Acosta and Trugeda<sup>9</sup> reported that an excess of dentine growth is frequently observed over the MB2 opening. Moreover, if radiopaque filling materials are present, they can generate artifacts by scattering which can significantly hamper visualization. It is widely established that the clinical and conventional radiographic examinations should be the first diagnostic methods for endodontic problems, but when these



examinations fail to answer the clinical difficulty, a great option for imaging research is the CBCT exam.

The validity of any diagnostic test largely depends on the reproducibility of their results.<sup>10</sup> Factors such as the quality of the images, conditions for their analysis, operator's skills and care during image acquisition strongly affects the incidence of diagnostic errors. Several reports confirm that the variability during the identification of MB2 is associated with method inaccuracies, which vary independently from the clinical or imaging method. Diagnosis errors can lead to an inappropriate endodontic treatment. They can also influence negatively the assessment of the treatment outcome.<sup>11-14</sup>

As the diagnosis of the MB2 is a determining factor to obtain a proper and precise endodontic treatment, the primary goal of this study was to specifically assess the ability of the three observers to accurately confirm the existence and absence of an MB2 canal in human first upper molars. Moreover, the present study assessed the inter-examiner agreement for the diagnosis of MB2 with CBCT when compared to the method of tooth clearing.

## **MATERIALS AND METHODS**

For this study, eighty-two extracted human first upper molars were selected from the Human Teeth Bank of Franciscan University (UNIFRA, Santa Maria, Rio Grande do Sul, Brazil). This study was approved by the Institutional Review Board of the Federal University of Rio Grande do Sul, Brazil.

The study design consisted in three steps, depending on MB1 condition:

Step 1 - image acquisition with both 0.3mm and 0.2mm voxel-size CBCT in non filled MB1 teeth;

Step 2 - image acquisition with both 0.3mm and 0.2mm voxel-size CBCT in MB1 filled teeth; and,

Step 3 - image acquisition with both 0.3mm and 0.2mm voxel-size CBCT in MB1 deobturated teeth.

The CBCT images were obtained in an i-CAT scanner (Imaging Sciences International, Inc, Hatfield, PA, USA; 120 kVp, 3-8 mA), where all samples were put together and placed on the desk of the i-CAT tomography. The sections were obtained with specific protocols based on the voxel resolution: 0.3-mm [8-cm field of view (FOV) x 17 cm (diameter), 20 seconds for acquisition] and 0.2-mm [8-cm FOVx 17 cm (diameter), 40 seconds for acquisition]. Images were analyzed using the i-CAT Vision software (Imaging Sciences International Inc, Hatfield, PA, USA).

After the tomographic acquisitions, all samples were clarified to directly visualize the presence of MB2. The external surface of each sample was covered with three layers of nail varnish, except the 3 mm region surrounding the apex of the tooth. The pulp chamber was filled with Indian ink (Royal Talens, Apeldoorn, Netherlands) and inserted in a vacuum chamber for 6 hours. Then, the excess of dye was removed by washing in tap water for a 6-hour period. For clearing procedures, the nails varnish was removed with a blade. Samples were immersed in 5% hydrochloric acid for 12 hours; washed in tap

water (4 hours); dehydrated in an ascending alcohol battery [75GL, 85GL, 95GL, 100GL] (3 hours each); and immersed in methyl salicylate for clarification. The configuration of the MB1 and MB2 in the mesiobuccal root was recorded through photographic imaging in a stereomicroscope (Leica Microsystems, Wetzlar, Germany). These images were considered the gold standard.

Three dentists from a post-graduate program in oral and maxillofacial radiology, with respectively five (1), three (2) and one (3) year of experience with CBCT, analyzed the images. All examiners were calibrated before image examination (Kappa >0.7).

The study followed a predetermined sequence for images examination. First, the observers randomly evaluated all 0.3-mm voxel images. After a period of 15 days, the examiners took in the analysis with 0.2-mm voxel size. Data regarding the presence or the absence of the MB2 were recorded in a spreadsheet and were analyzed in the PASW v.19.0 for Windows (SPSS, Chicago, IL, USA). The Kappa value was calculated.

## **RESULTS**

The MB2 root canal was present in 55/82 teeth through the clearing method. The prevalence of MB2 as identified with different voxel sizes and MB1 condition, for each observer, are listed in Table 1. In non filled MB1 teeth, considering both 0.3-mm and 0.2-mm voxel-size images, MB2 detection ranged from 45 to 55 teeth. However, in the MB1 filled group, the results were

influenced by the voxel size. A high number of true-positive diagnosis was observed for the 0.2-mm voxel-size images. There was an increase in the MB2 detection in teeth with deobturated MB1 root canals, unlike other studies.

Table 2 shows the Kappa value among observers for both 0.2-mm and 0.3-mm with different MB1 conditions. The reproducibility among evaluators to correctly detect the presence or absence of MB2 was higher for 0.2-mm and 0.3-mm voxel-sizes in the group with non filled MB1, when compared specially to the filled MB1. The deobturated group shows lower Kappa values when compared to the group with non-filled MB1.

Graphs 1, 2 and 3 show the interactions among three evaluators through the Kappa coefficient and its confidence interval (CI). It can be observed that the differences were specially found in Graphic 2 (observer 1 vs. 3) and 3 (observer 2 vs. 3) in non filled groups when compared with the MB1 filled condition.

## **DISCUSSION**

Different methods have been advocated for use in visualizing root canal systems in extracted teeth. Cross and longitudinal sectioning of roots, as well as scanning electron microscopy are some of the methods used to view the canal shape, but have the disadvantage of visualizing only a limited area of tooth structure.<sup>15</sup> Clearing and radiographic techniques are other commonly used methods.<sup>16-18</sup>

Recently, CBCT has been widely used in implantology, maxillofacial reconstruction, and in endodontic diagnosis before surgical endodontics as well as for assessment of canal preparation, obturation, and removal of root fillings.<sup>19, 20</sup> Although it is known that CBCT provides more accurate imaging information about the diagnosis of endodontic diseases and conditions, there is little evidence on the influence of the root canal filling in the detection of MB2.

Blattner et al.<sup>21</sup> refer in their study that a positive correlation between CBCT scans and clinical sectioning diagnoses was present in 79.0% of your samples. Although not yet at 100% accuracy, CBCT scans certainly show promise as a modality to add to the endodontic armamentarium, particularly in nonsurgical root canal retreatment situations in which the MB2 canal was not initially treated.

Matherne et al.<sup>6</sup> analyzed seventy-two extracted teeth with the charged coupled device (CCD) and photostimulable phosphor plate (PSP) digital radiography for identifying root canal systems. The CBCT were used to establish “ground truth” for the comparisons and were evaluated by a board-certified oral and maxillofacial radiologist who determined the number of root canal systems. The authors concluded that for the endodontist evaluators with either CCD or PSP methods failed to identify at least 1 root canal systems in approximately 4 of 10 teeth, which can result in a less optimal healing outcome if a missed root canal systems is left uninstrumented and unobturated.

In this study, the observers identified a high number of MB2 with CBCT 0.3-mm and 0.2-mm voxel sizes when compared with the number of absence of MB2 identified in these same images. The presence of root canal filling

promoted the most important difficulty in MB2 diagnosis even for its presence and absence. Previous studies reported a decrease in the CBCT specificity when the root canal filling was present because it produces streaking artifacts.<sup>22, 23</sup> Then the method of tooth clearing was used to establish “ground truth” and not the CBCT.

When the reproducibility between each examiner was assessed, it was observed that more linear results were provided by experienced observers. However the greatest differences still remained between the groups with non filled MB1, regardless the voxel size and each experienced observer. These results differed from the previous literature findings<sup>14</sup> and also suggested that the experience in evaluating CBCT images was a factor that did not significantly influenced the results in this study.

The radiation dose should be considered when an radiographic or tomographic exam is requested, and it is known that the voxel size is directly linked to patient's exposure to radiation.<sup>19, 24</sup> In the present study, the correct diagnosis for the MB2 presence or absence were high and similar for 0.2-voxel resolution scans for the groups with MB1 no filled and deobturated. However, the 0.3-voxel scans seemed to present some difficult in detection of MB2 when the MB1 was filled, suggesting that in these cases the choice of the 0.2-mm could be a good strategy.

Bauman et al.<sup>25</sup>, evaluating twenty-four samples with four different voxel sizes and seven examiners, analyzed the intra-rater reliability to detect the maxillary mesiobuccal canals. The authors concluded that the reliability of detection of MB2 canals in CBCT scans increased as the resolution improved.

In this study, the Kappa for the reproducibility (inter-rater reliability) among observers showed that the values remained constant between 0.3-mm and 0.2-mm voxel resolution. However, the root condition seems to be more important for results than the voxel size. For empty roots the Kappa had greater results for the tested parameters, followed respectively by the groups with MB1 obturated and filled.

It is true that technological advance will need to take place in order to produce even more precise CBCT imaging of MB2 canals. Both the CBCT unit and software's used to manipulate the images will need steady improvement. It will also be necessary for the oral radiologist and possibly even the endodontists to increase more training related specifically to the diagnosis of canals system using CBCT technology. The results of this in vitro investigation can be interpreted to show that CBCT images still need to be widely studied in order to achieve superior reproducibility values.

Table 1: Correct identification of MB2 by a total number of 82 teeth according the voxel size and root condition (a total of 55 for presence and 27 for absence).

Voxel size and root condition	Observer					
	1		2		3	
	P MB2	A MB2	P MB2	A MB2	P MB2	A MB2
0.3-mm MB1 no filled	45	23	52	19	51	23
0.3-mm MB1 filled	38	10	38	10	44	15
0.3-mm MB1 deobturated	40	16	46	13	42	13
0.2-mm MB1 no filled	52	22	53	19	55	14
0.2-mm MB1 filled	37	16	48	17	55	11
0.2-mm MB1 deobturated	48	13	51	18	53	14

P MB2 = presence of MB2 (total 55)      A MB2 = absence of MB2 (total 27)

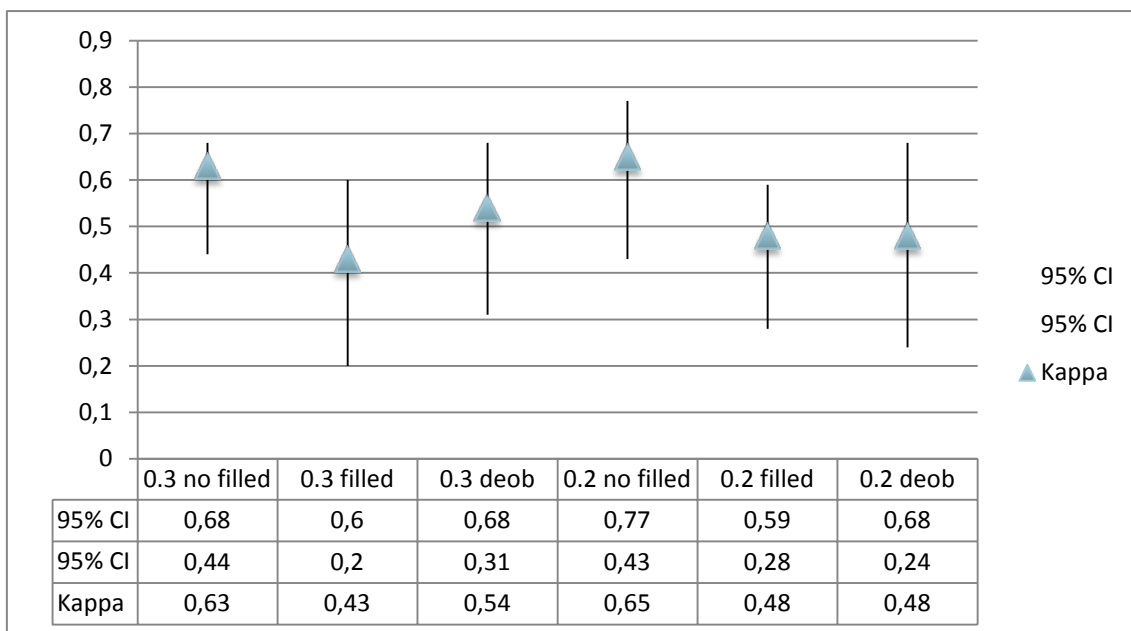
Table 2: Kappa value among observers for 0.2-mm and 0.3-mm voxel sizes in different root condition.

Root Condition	Voxel size	
	0.3-mm	0.2-mm
MB1 no filled	0.68	0.62
MB1 filled	0.39	0.39
MB1 deobturated	0.51	0.56



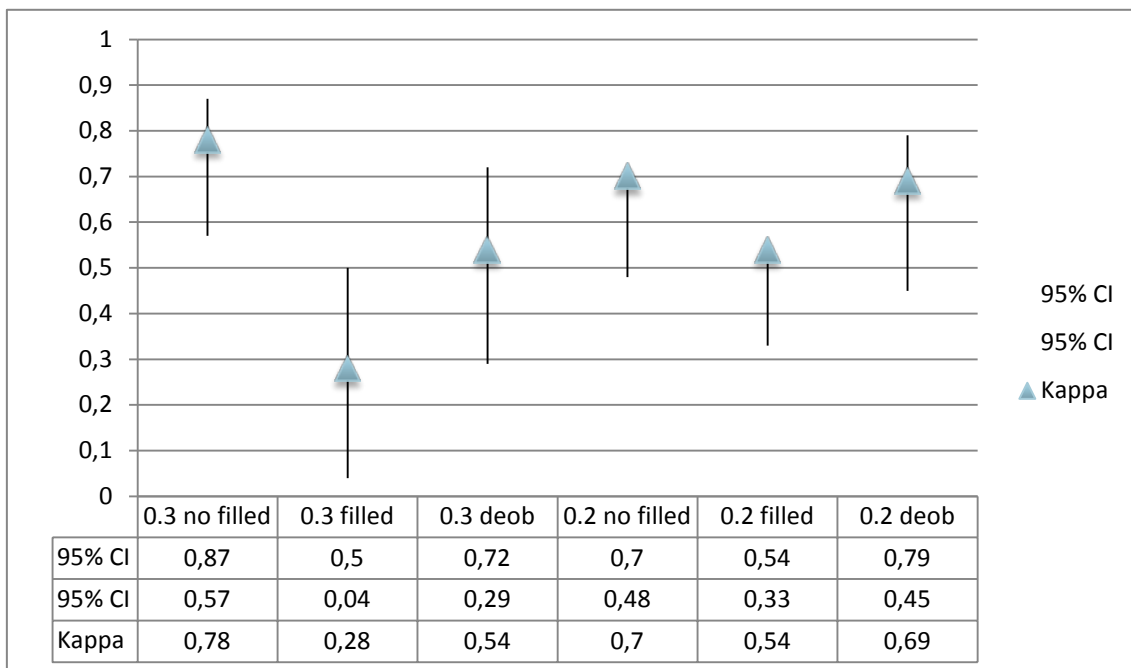
Graphic 1: Kappa value and confidence interval (95%) between observers 1 vs

2.

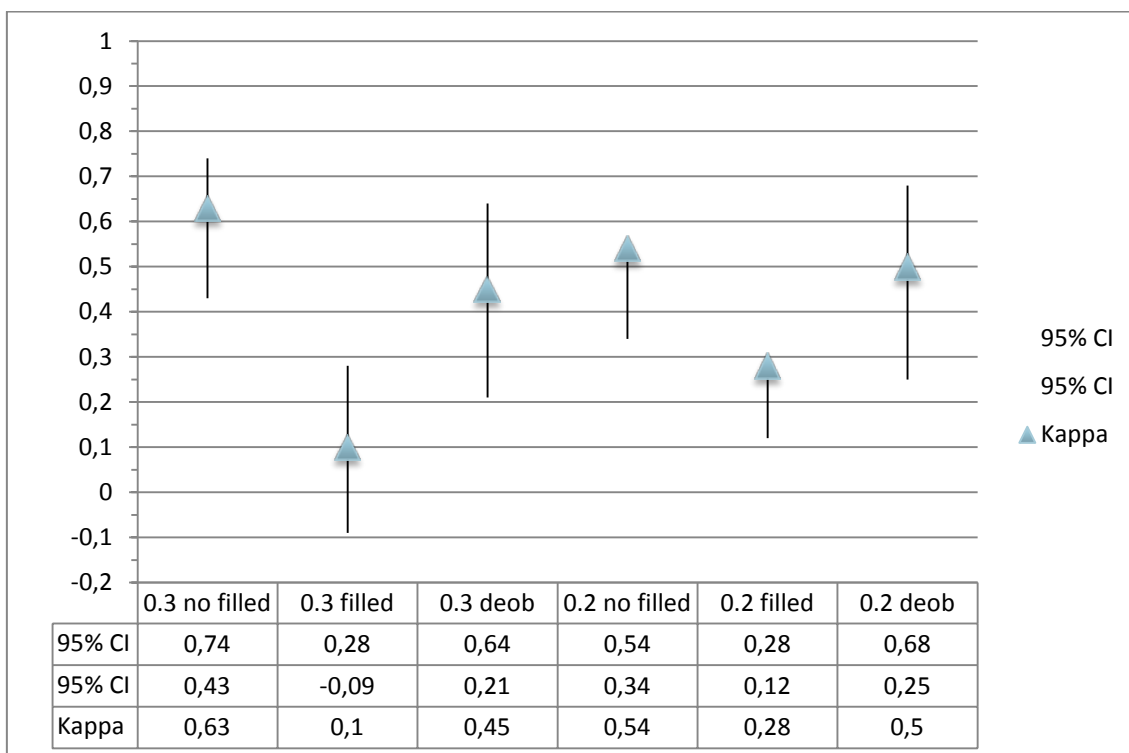


Graphic 2: Kappa value and confidence interval (95%) between observers 1 vs

3.



Graphic 3: Kappa value and confidence interval (95%) between observers 2 vs 3.



## REFERENCES

- [1] Cotton TP, Geisler TM, Holden DT, Schwartz SA, Schindler WG. Endodontic applications of cone-beam volumetric tomography. J Endod 2007 Sep;33:1121-1132.
- [2] Simon JH, Enciso R, Malfaz JM, Roges R, Bailey-Perry M, Patel A. Differential diagnosis of large periapical lesions using cone-beam computed tomography measurements and biopsy. J Endod 2006 Sep;32:833-837.

- [3] Kulild JC, Peters DD. Incidence and configuration of canal systems in the mesiobuccal root of maxillary first and second molars. *J Endod* 1990 Jul;16:311-317.
- [4] Omer OE, Al Shalabi RM, Jennings M, Glennon J, Claffey NM. A comparison between clearing and radiographic techniques in the study of the root-canal anatomy of maxillary first and second molars. *Int Endod J* 2004 May;37:291-296.
- [5] Tachibana H, Matsumoto K. Applicability of X-ray computerized tomography in endodontics. *Endod Dent Traumatol* 1990 Feb;6:16-20.
- [6] Matherne RP, Angelopoulos C, Kulild JC, Tira D. Use of cone-beam computed tomography to identify root canal systems in vitro. *J Endod* 2008 Jan;34:87-89.
- [7] Patel S, Dawood A, Whaites E, Pitt Ford T. New dimensions in endodontic imaging: part 1. Conventional and alternative radiographic systems. *Int Endod J* 2009 Jun;42:447-462.
- [8] Baratto Filho F, Zaitter S, Haragushiku GA, de Campos EA, Abuabara A, Correr GM. Analysis of the internal anatomy of maxillary first molars by using different methods. *J Endod* 2009 Mar;35:337-342.
- [9] Acosta Vigouroux SA, Trugeda Bosaans SA. Anatomy of the pulp chamber floor of the permanent maxillary first molar. *J Endod* 1978 Jul;4:214-219.
- [10] Lou L, Lagravere MO, Compton S, Major PW, Flores-Mir C. Accuracy of measurements and reliability of landmark identification with computed tomography (CT) techniques in the maxillofacial area: a systematic review. *Oral Surg Oral Med Oral Pathol Oral Radiol Endod* 2007 Sep;104:402-411.
- [11] Kim S. Modern endodontic practice: instruments and techniques. *Dent Clin North Am* 2004 Jan;48:1-9.
- [12] Vertucci FJ. The endodontic significance of the mesiobuccal root of the maxillary first molar. *US Navy Med* 1974 May;63:29-31.

- [13] Saunders WP, Saunders EM. Conventional endodontics and the operating microscope. *Dent Clin North Am* 1997 Jul;41:415-428.
- [14] Corcoran J, Apicella MJ, Mines P. The effect of operator experience in locating additional canals in maxillary molars. *J Endod* 2007 Jan;33:15-17.
- [15] Weine FS, Healey HJ, Gerstein H, Evanson L. Canal configuration in the mesiobuccal root of the maxillary first molar and its endodontic significance. *Oral Surg Oral Med Oral Pathol* 1969 Sep;28:419-425.
- [16] Pecora JD, Woelfel JB, Sousa Neto MD, Issa EP. Morphologic study of the maxillary molars. Part II: Internal anatomy. *Braz Dent J* 1992;3:53-57.
- [17] Alavi AM, Opananon A, Ng YL, Gulabivala K. Root and canal morphology of Thai maxillary molars. *Int Endod J* 2002 May;35:478-485.
- [18] Pineda F, Kuttler Y. Mesiodistal and buccolingual roentgenographic investigation of 7,275 root canals. *Oral Surg Oral Med Oral Pathol* 1972 Jan;33:101-110.
- [19] Scarfe WC, Farman AG, Sukovic P. Clinical applications of cone-beam computed tomography in dental practice. *J Can Dent Assoc* 2006 Feb;72:75-80.
- [20] Patel S. New dimensions in endodontic imaging: Part 2. Cone beam computed tomography. *Int Endod J* 2009 Jun;42:463-475.
- [21] Blattner TC, George N, Lee CC, Kumar V, Yelton CD. Efficacy of cone-beam computed tomography as a modality to accurately identify the presence of second mesiobuccal canals in maxillary first and second molars: a pilot study. *J Endod* 2010 May;36:867-870.
- [22] Hassan B, Metska ME, Ozok AR, van der Stelt P, Wesselink PR. Detection of vertical root fractures in endodontically treated teeth by a cone beam computed tomography scan. *J Endod* 2009 May;35:719-722.
- [23] Melo SL, Bortoluzzi EA, Abreu M, Jr., Correa LR, Correa M. Diagnostic ability of a cone-beam computed tomography scan to assess longitudinal root fractures in prosthetically treated teeth. *J Endod* 2010 Nov;36:1879-1882.

[24] Ludlow JB, Davies-Ludlow LE, Brooks SL. Dosimetry of two extraoral direct digital imaging devices: NewTom cone beam CT and Orthophos Plus DS panoramic unit. *Dentomaxillofac Radiol* 2003 Jul;32:229-234.

[25] Bauman R, Scarfe W, Clark S, Morelli J, Scheetz J, Farman A. Ex vivo detection of mesiobuccal canals in maxillary molars using CBCT at four different isotropic voxel dimensions. *Int Endod J* 2011 Aug;44:752-758.

Sabe-se da importância de um adequado exame clínico previamente à solicitação de qualquer exame de imagem e também das diferentes condições clínicas que podem influenciar na qualidade do diagnóstico e, conseqüentemente, definir protocolos específicos para cada situação. Dentre os métodos de imagem bastante utilizados na Odontologia, a tomografia computadorizada de feixe cônico tem sido foco de muitas pesquisas em diversas áreas.

Os resultados desse estudo apontam a radiografia convencional como um método pouco acurado para a detecção de canais MP, independente da situação clínica do canal MV. A TCFC, por sua vez, apresentou-se como um exame confiável para investigar a presença desse canal, sendo que, para dentes com o canal MV obturado, o voxel de 0,2-mm mostrou-se como melhor opção, enquanto que, para dentes sem material endodôntico no canal MV o voxel 0,3-mm deve ser utilizado, considerando a menor dose de radiação a que o paciente é exposto.

Em relação à reprodutibilidade de diagnóstico da TCFC para o canal MP, pode-se concluir que a condição do canal MV foi o fator mais relevante para a variação nos resultados, quando comparado ao tamanho do voxel e experiência do examinador.

Assim, destaca-se a importância de estudos que definam protocolos de aquisição tomográfica para cada situação clínica, fazendo com que a utilização correta do exame e seu protocolo adequado o torne mais acurado. Considerando-se a relação custo-benefício e, em especial, a redução na dose

de radiação ao paciente, mais casos poderão ser corretamente diagnosticados quando for explorada toda a potencialidade da técnica escolhida.

1. Hartwell, G., et al., *The incidence of four canals in maxillary first molars: a clinical determination*. J Am Dent Assoc, 2007. **138**(10): p. 1344-6.
2. Kulild, J.C. and D.D. Peters, *Incidence and configuration of canal systems in the mesiobuccal root of maxillary first and second molars*. J Endod, 1990. **16**(7): p. 311-7.
3. Weng, X.L., et al., *Root canal morphology of permanent maxillary teeth in the Han nationality in Chinese Guanzhong area: a new modified root canal staining technique*. J Endod, 2009. **35**(5): p. 651-6.
4. Pattanshetti, N., M. Gaidhane, and A.M. Al Kandari, *Root and canal morphology of the mesiobuccal and distal roots of permanent first molars in a Kuwait population--a clinical study*. Int Endod J, 2008. **41**(9): p. 755-62.
5. Cleghorn, B.M., W.H. Christie, and C.C. Dong, *Root and root canal morphology of the human permanent maxillary first molar: a literature review*. J Endod, 2006. **32**(9): p. 813-21.
6. Alavi, A.M., et al., *Root and canal morphology of Thai maxillary molars*. Int Endod J, 2002. **35**(5): p. 478-85.
7. Weine, F.S., et al., *Canal configuration in the mesiobuccal root of the maxillary first molar and its endodontic significance*. Oral Surg Oral Med Oral Pathol, 1969. **28**(3): p. 419-25.
8. Vertucci, F.J., *Root canal anatomy of the human permanent teeth*. Oral Surg Oral Med Oral Pathol, 1984. **58**(5): p. 589-99.
9. Vertucci, F.J., *The endodontic significance of the mesiobuccal root of the maxillary first molar*. US Navy Med, 1974. **63**(5): p. 29-31.
10. Pecora, J.D., et al., *Morphologic study of the maxillary molars. Part II: Internal anatomy*. Braz Dent J, 1992. **3**(1): p. 53-7.
11. Green, D., *Double canals in single roots*. Oral Surg Oral Med Oral Pathol, 1973. **35**(5): p. 689-96.



12. Weller, R.N., S.P. Niemczyk, and S. Kim, *Incidence and position of the canal isthmus. Part 1. Mesiobuccal root of the maxillary first molar*. J Endod, 1995. **21**(7): p. 380-3.
13. Teixeira, F.B., et al., *A preliminary in vitro study of the incidence and position of the root canal isthmus in maxillary and mandibular first molars*. Int Endod J, 2003. **36**(4): p. 276-80.
14. Stropko, J.J., *Canal morphology of maxillary molars: clinical observations of canal configurations*. J Endod, 1999. **25**(6): p. 446-50.
15. Iqbal, M. and E. Fillmore, *Preoperative predictors of number of root canals clinically detected in maxillary molars: a PennEndo Database study*. J Endod, 2008. **34**(4): p. 413-6.
16. Corcoran, J., M.J. Apicella, and P. Mines, *The effect of operator experience in locating additional canals in maxillary molars*. J Endod, 2007. **33**(1): p. 15-7.
17. Hess, W.Z., E, *The anatomy of the root canals of the teeth of the permanent and deciduous dentitions*. William Wood & Co., 1925: p. 1-39.
18. Sempira, H.N. and G.R. Hartwell, *Frequency of second mesiobuccal canals in maxillary molars as determined by use of an operating microscope: a clinical study*. J Endod, 2000. **26**(11): p. 673-4.
19. Kim, S., *Modern endodontic practice: instruments and techniques*. Dent Clin North Am, 2004. **48**(1): p. 1-9.
20. Patel, S., et al., *New dimensions in endodontic imaging: part 1. Conventional and alternative radiographic systems*. Int Endod J, 2009. **42**(6): p. 447-62.
21. Plotino, G., et al., *Three-dimensional imaging using microcomputed tomography for studying tooth macromorphology*. J Am Dent Assoc, 2006. **137**(11): p. 1555-61.
22. Omer, O.E., et al., *A comparison between clearing and radiographic techniques in the study of the root-canal anatomy of maxillary first and second molars*. Int Endod J, 2004. **37**(5): p. 291-6.
23. Buhrlay, L.J., et al., *Effect of magnification on locating the MB2 canal in maxillary molars*. J Endod, 2002. **28**(4): p. 324-7.

24. Baratto Filho, F., et al., *Analysis of the internal anatomy of maxillary first molars by using different methods*. J Endod, 2009. **35**(3): p. 337-42.
25. Programs, A.o.A.S.f.E. (2008) <http://www.ada.org/sections/educationAndCareers/pdfs/endo.pdf>.  
**Volume,**
26. Kim, S. and S. Baek, *The microscope and endodontics*. Dent Clin North Am, 2004. **48**(1): p. 11-8.
27. Saunders, W.P. and E.M. Saunders, *Conventional endodontics and the operating microscope*. Dent Clin North Am, 1997. **41**(3): p. 415-28.
28. Gorduysus, O., et al., *Localization of root canal orifices in mandibular second molars in relation to occlusal dimension*. Int Endod J, 2009. **42**(11): p. 973-7.
29. Liedke, G.S., et al., *Influence of voxel size in the diagnostic ability of cone beam tomography to evaluate simulated external root resorption*. J Endod, 2009. **35**(2): p. 233-5.
30. Lermen, C.A., et al., *Comparison between two tomographic sections in the diagnosis of external root resorption*. J Appl Oral Sci, 2010. **18**(3): p. 303-7.
31. da Silveira, H.L., et al., *Diagnostic ability of computed tomography to evaluate external root resorption in vitro*. Dentomaxillofac Radiol, 2007. **36**(7): p. 393-6.
32. Cotton, T.P., et al., *Endodontic applications of cone-beam volumetric tomography*. J Endod, 2007. **33**(9): p. 1121-32.
33. Matherne, R.P., et al., *Use of cone-beam computed tomography to identify root canal systems in vitro*. J Endod, 2008. **34**(1): p. 87-9.
34. Patel, S., et al., *The potential applications of cone beam computed tomography in the management of endodontic problems*. Int Endod J, 2007. **40**(10): p. 818-30.
35. Araki, K., et al., *Characteristics of a newly developed dentomaxillofacial X-ray cone beam CT scanner (CB MercuRay): system configuration and physical properties*. Dentomaxillofac Radiol, 2004. **33**(1): p. 51-9.
36. Hilgers, M.L., et al., *Accuracy of linear temporomandibular joint measurements with cone beam computed tomography and digital*

- cephalometric radiography*. Am J Orthod Dentofacial Orthop, 2005. **128**(6): p. 803-11.
37. Lagravere, M.O. and P.W. Major, *Proposed reference point for 3-dimensional cephalometric analysis with cone-beam computerized tomography*. Am J Orthod Dentofacial Orthop, 2005. **128**(5): p. 657-60.
  38. Scarfe, W.C., A.G. Farman, and P. Sukovic, *Clinical applications of cone-beam computed tomography in dental practice*. J Can Dent Assoc, 2006. **72**(1): p. 75-80.
  39. Ramamurthy, R., et al., *Effects of imaging system and exposure on accurate detection of the second mesio-buccal canal in maxillary molar teeth*. Oral Surg Oral Med Oral Pathol Oral Radiol Endod, 2006. **102**(6): p. 796-802.
  40. Cevidanes, L.H., M.A. Styner, and W.R. Proffit, *Image analysis and superimposition of 3-dimensional cone-beam computed tomography models*. Am J Orthod Dentofacial Orthop, 2006. **129**(5): p. 611-8.
  41. Tachibana, H. and K. Matsumoto, *Applicability of X-ray computerized tomography in endodontics*. Endod Dent Traumatol, 1990. **6**(1): p. 16-20.
  42. Blattner, T.C., et al., *Efficacy of cone-beam computed tomography as a modality to accurately identify the presence of second mesiobuccal canals in maxillary first and second molars: a pilot study*. J Endod. **36**(5): p. 867-70.
  43. Sanders, M.A., et al., *Common orthodontic appliances cause artifacts that degrade the diagnostic quality of CBCT images*. J Calif Dent Assoc, 2007. **35**(12): p. 850-7.
  44. Patel, S., *New dimensions in endodontic imaging: Part 2. Cone beam computed tomography*. Int Endod J, 2009. **42**(6): p. 463-75.
  45. Lee, J.K., et al., *Quantitative three-dimensional analysis of root canal curvature in maxillary first molars using micro-computed tomography*. J Endod, 2006. **32**(10): p. 941-5.
  46. Vier-Pelisser, F.V., et al., *The anatomy of the root canal system of three-rooted maxillary premolars analysed using high-resolution computed tomography*. Int Endod J. **43**(12): p. 1122-31.

47. SedentexCT. *Radiation Protection: Cone Beam for Dental and Maxillofacial Radiology. Evidenced Based Guidelines 2011*. 2011 [cited 2011 03.09.2011].

## Aprovação no Comissão de Pesquisa – FO-UFRGS

Projetos

Página 1 de 1

**Sistema Pesquisa - Pesquisador: Heloisa Emilia Dias Da Silveira**

**Projeto Nº:** 20145

**Título:** ESTUDO MORFOLOGICO DA CAMARA PULPAR E RAIZ MESIO-VESTIBULAR DO PRIMEIRO MOLAR SUPERIOR - ANALISE VISUAL, RADIOGRAFICA E TOMOGRAFICA

COMISSAO DE PESQUISA DE ODONTOLOGIA: Parecer

APROVADO EM REUNIÃO DA COMPESQ EM 21/01/11 - ATA UNIFICADA 01/11. O PROJETO DEVE SER ENCAMINHADO AO COMITÊ DE ÉTICA.

## Aprovação no Comitê de Ética - UFRGS

---

Projetos

Página 1 de 1

**Sistema Pesquisa - Pesquisador: Heloisa Emilia Dias Da Silveira**

**Projeto Nº:** 20145

**Título:** ESTUDO MORFOLOGICO DA CAMARA PULPAR E RAIZ MESIO-VESTIBULAR DO PRIMEIRO MOLAR SUPERIOR - ANALISE VISUAL, RADIOGRAFICA E TOMOGRAFICA

COMITE DE ETICA EM PESQUISA DA UFRGS: **Parecer favorável**

O projeto intitulado "Estudo morfológico da câmara pulpar e raiz méso-vestibular do primeiro molar superior - análise visual, radiográfica e tomográfica" tem por objetivos (1) determinar a ocorrência do canal méso-palatino em uma amostra de primeiros molares superiores humanos extraídos; (2) estudar a posição espacial da embocadura do canal méso-palatino em relação ao canal méso-vestibular; (3) descrever a configuração anatômica dos canais méso-vestibular e méso-palatino através da tomografia computadorizada de feixe cônico e (4) avaliar a capacidade diagnóstica da radiografia convencional e da tomografia computadorizada de feixe cônico na detecção do canal méso-palatino em diferentes situações: canal mésovestibular vazio, obturado e após a desobturação. Trata-se de um estudo in vitro com 93 dentes extraídos provenientes do Banco de Dentes do Curso de Odontologia do Centro Universitário Franciscano. Os espécimes serão submetidos à exame visual microscópico, exame radiográfico com dissociações e exame tomográfico. O projeto foi aprovado pela Compesq da Unidade e trata-se de um projeto de doutorado. A fundamentação teórica embasa de forma adequada o problema a ser abordado. O cronograma e o orçamento estão adequados, o estudo será custeado com recursos próprios dos pesquisadores.