



Development of experimental sporotrichosis in a murine model with yeast and mycelial forms of *Sporothrix schenckii**

Avaliação do desenvolvimento da esporotricose experimental em camundongos com as formas leveduriforme e filamentosa do *Sporothrix schenckii*

Márcia de Oliveira Nobre¹, Tatiana de Ávila Antunes², Izamara Aparecida de Oliveira³, Vanessa Berg³, Thomaz Lucia Jr.⁴, Cristina Gevehr Fernandes⁴, Mário Carlos Araújo Meireles⁵ & Laerte Ferreira^{1,3}

ABSTRACT

Sporotrichosis is a subcutaneous disease that affects both men and a variety of animals caused by the dimorphic fungus *Sporothrix schenckii*. The aims of this study were to observe differences in virulence between inocula containing the yeast (Y) or mycelial (M) forms, to compare the reactions induced by the two inocula injected in different anatomical sites, and to verify the possibility of horizontal transmission of the disease by contact between infected and healthy animals. All animals were observed during a period of nine weeks. Mice were inoculated subcutaneously in the paw pads and in the regions of the hip and shoulder joints. Another group of non-inoculated healthy mice was kept in direct contact with mice developing the subcutaneous lesions. Animals of groups Y and M developed lesions due to infections and clinical symptoms very characteristic of sporotrichosis. Lesions were more prominent and with longer duration when occurring in the pads than in any other site of inoculation. Non-inoculated mice remained healthy as it occurred to animals in the control group. The development of typical clinical symptoms for sporotrichosis in all inoculated groups suggests that no difference exists in virulence between the yeast and mycelial forms of the same isolated of *S. schenckii*. Moreover, the paw pads appear to be the site of choice for the inoculation for experimental sporotrichosis in the murine model. In addition, this study also showed that the contact with sick animals and contaminated materials is insufficient to transmit the infection to immune competent animals with intact skin.

Key words: *Sporothrix schenckii*, experimental sporotrichosis, yeast form, mycelial form, murine model, mice.

RESUMO

A esporotricose é uma micose subcutânea causada pelo fungo dimórfico *Sporothrix schenckii* que acomete o homem e uma grande variedade de animais. Este trabalho teve como objetivos verificar possíveis diferenças de virulência entre inóculos das formas leveduriforme (Y) e filamentosa (M), comparar as reações induzidas pelos dois inóculos em diferentes sítios anatômicos, além de verificar a possibilidade da ocorrência de transmissão de animais doentes para sadios. Durante um período de nove semanas, foi observado o desenvolvimento da esporotricose experimental em camundongos inoculados via subcutânea na almofadinha plantar e nas regiões das articulações escapuloumeral e coxofemural. Também, camundongos não inoculados foram mantidos em contato direto com os que estavam desenvolvendo lesões subcutâneas. Os animais dos grupos Y e M desenvolveram quadro clínico muito semelhante de esporotricose. Os inóculos provocaram lesões mais evidentes e duradouras na almofadinha plantar do que nos outros sítios de inoculação. Os camundongos não inoculados permaneceram hígidos à semelhança da situação observada no grupo controle. O desenvolvimento de quadro clínico semelhante de esporotricose entre os grupos sugere que, *a priori*, não existam diferenças entre os inóculos das formas leveduriforme e filamentosa de um mesmo isolado de *S. schenckii*. Os resultados também indicam que a almofadinha plantar pode ser considerada como ponto de inoculação preferencial no modelo murino de esporotricose experimental, além de comprovar que o simples contato de animais imunocompetentes, sem aparentes lesões de continuidade, com animais e materiais contaminados não é suficiente para o desenvolvimento da esporotricose.

Descritores: *Sporothrix schenckii*, esporotricose experimental, forma leveduriforme, forma filamentosa, modelo murino, camundongos.

Received: May 2003

Accepted: October 2003

* Manuscript based on a Dissertation submitted by the senior author in partial fulfillment of requirements for the degree of Doctor in Veterinary Sciences, Post Graduated Program in Veterinary Sciences (Programa de Pós-Graduação em Ciências Veterinárias), Faculdade de Veterinária (FAVET) - UFRGS. ¹Programa de Pós-Graduação em Ciências Veterinárias (PPGCV) - UFRGS. ²PPG em Veterinária - UFPEL. ³Setor de Micologia, Departamento de Patologia Clínica Veterinária, FAVET/UFRGS. ⁴Departamento de Patologia Animal e ⁵Departamento de Veterinária Preventiva, FAVET/UFPEL. CORRESPONDENCE: M.O. Nobre [monobre@brturbo.com.br ; FAX: + 55 51 3316 7305].

INTRODUCTION

Sporotrichosis is a subcutaneous mycosis that has the dimorphic fungus *Sporothrix schenckii* as its causative agent. The disease occurs in men (work-related dermatosis) and in a great variety of animals such as dogs, cats, horses, cattle, camels, goats, mules, swine, rats, chimpanzee, birds and dolphins [4,5,7]. The habitat of the fungus is soil rich in organic matter but it grows in plants and tree bark in warm environments with high humidity [4]. The dimorphic organism is mycelial in the environment or *in vitro* in temperatures inferior to 37°C and yeast-like *in vivo* or *in vitro* at 37°C [6].

With this work we aimed to verify possible differences in the virulence between inocula of mycelial and yeast forms of *S. schenckii* comparing the reactions produced using three different sites of inoculation in mice. Moreover, we tested the possibility of transmission of this mycosis from affected animals to healthy ones.

MATERIALS AND METHODS

A thermostable isolate of *Sporothrix schenckii* with pigmented conidia obtained from a clinical case of feline cutaneous sporotrichosis was used. Yeast inoculum was cultured in liquid medium (Brain-Heart broth®) at 37°C for 10 days and kept in a shaker at 800 cycles per minute. Following this, cultures were filtered in a double layer of sterile gauze, centrifuged at 1500rpm for 15 minutes and washed twice in PBS. Mycelial inoculum was cultured on 4% Sabouraud's dextrose-agar® in plates at 25°C for 10 days. Mycelium was removed using a blade and washed twice in PBS. It was filtered twice in a double layer of sterile gauze and centrifuged at 1500rpm for 15 minutes.

Fifty-eight 7 weeks old-male-mice (*Swiss albino*) were divided in three groups of 18 animals each. Control group animals (group C) received PBS; group Y mice were inoculated with the yeast form of *S. schenckii* and, group M with the mycelial form of the same isolate of the fungus. The left posterior paw pad and the regions of right hip and right shoulder of each inoculated mice received a subcutaneous injection with 0.1mL of the suspension containing 2×10^3 cells of *S. schenckii*/mL. And another two healthy mice with intact skin were kept in direct contact with the inoculated ones in each of the experimental groups.

Mice were observed daily for the development of sporotrichosis during the nine following weeks. The external diameter of the lesions in the sites of inoculation were taken weekly with a sliding calliper and the lesions size were used as a parameter to estimate the clinical evolution of the disease.

Four necropsies were realized in the second, forth, sixth and ninth weeks respectively to collect samples from the inoculation sites and other areas when dissemination of the mycosis was seen. Histopathology and mycological tests were realized to identify the organism *S. schenckii* with PAS method for the histopathology and samples culture. Samples were cultured in two plates containing Sabouraud's dextrose with chloramphenicol and cycloheximide (Bacto mycobiologic agar®) at 25°C and 37°C during 10 days.

Statistics was made with Statistix 7.0 (Statistix, 2000) using frequency distribution of the diameter of the lesions at sites of inoculation and clinical evolution of the disease related to inocula with the yeast (Y) and mycelial (M) form. Kruskal-Wallis method for analysis of variance of non-parametric data was used for differences between treatments due to the absence of a normal distribution.

RESULTS

Animals of groups Y and M developed clinical picture of sporotrichosis with similar clinical evolution. A small swelling at the inoculation sites was noted in 24 hours following the inoculation in all animals including the control group and that disappeared in 48 hours. First lesions were noted after the fifth day with moderate edema and erythema of the paw pad that became more severe on the sixth and seventh days. At this time, mice showed an increased edema and erythema and some cyanotic points in the paw pad and had small nodules in the inoculated regions of the hip and shoulder.

Lesions were more evident in the paw pads of animals of both Y and M groups from the second until the forth week with mice presenting ulcers, crusts, necrosis and exudate with persistent edema and erythema.

In relation to the different inocula, 50% of group Y animals had necrosis with exudate in the second week against 67% of group M animals. And this changed to 57% and 64% in the following week respectively for the groups. In the forth week there was an evident

reduction of lesions of group Y animals to 15% when group M had 50% of the animals still presenting the same clinical picture described above. In the fifth and sixth weeks healing of lesions started to take place in both groups. And in the eighth and ninth weeks 80% of Y group mice and 20% of group M showed complete remission of lesions in the paw pads.

Hip and shoulder regions showed ulcers, crusts and necrosis between the second and the sixth week with exudate until the fifth week. In the third week, about 70% of group Y animals and 65% of group M had exudate and in the fifth week 50% of group Y and 30% of group M were healing. A complete remission of lesions in the hip and shoulder occurred in the seventh week for both groups Y and M with those areas having the same clinical aspect of the control group.

Moreover, both groups Y and M had cutaneous lesions on the tail, testicles (Figure 1) and thighs between weeks 4 and 6 following the inoculation what characterized a picture of experimental sporotrichosis. A total of two animals died of systemic sporotrichosis during the course of the experiment being one animal of each one of the inoculated groups (groups Y and M).

There were no significant differences ($p>0.05$) in the average diameter of lesions between groups Y and M. The average diameter of the intact skin in the paw pads of all 58 studied animals was 1.2mm and 1.1mm for the regions of hips and shoulders what was observed for the animals in control group during all experimental period. In the first week the average diameter of lesions in the paw pads for the two groups

was 3.4mm. In the second week the average values reached their maximums of 4.2mm (Y) and 4.9mm (M) that suffered a gradual decrease of 1.6mm and 2.2mm respectively until the ninth week. In the hip and shoulder regions the diameters increased from the second week and in the seventh week they returned to the 1.1mm initial value (Figure 2). The alterations in the paw pad were the first ones to appear and they lasted until the end of the experiment (Figure 3).

Sporothrix schenckii was cultured from material collected from the three first necropsies realized in both groups. The fungus was found in the inoculation sites and other regions of the skin that presented lesions (thighs, testicles and tail) as well as from internal organs (liver, spleen, mesenteric ganglions and lungs) of the two animals with systemic sporotrichosis.

Histopathology alterations were more evident in the samples of the first two necropsies with granuloma presenting areas of necrosis having round or elliptical yeast cells. Also, a great infiltration of inflammatory cells with neutrophils, macrophages and giant cells was found. Samples of the third necropsy had less evident lesions corresponding to tissue repair and the last necropsy material showed evident scar reaction and isolation of the agent could no longer be obtained.

The four not inoculated animals kept in the same boxes with groups developing sporotrichosis (Y and M) did not show any alterations in their healthy state from the beginning to the end of the experimental period.

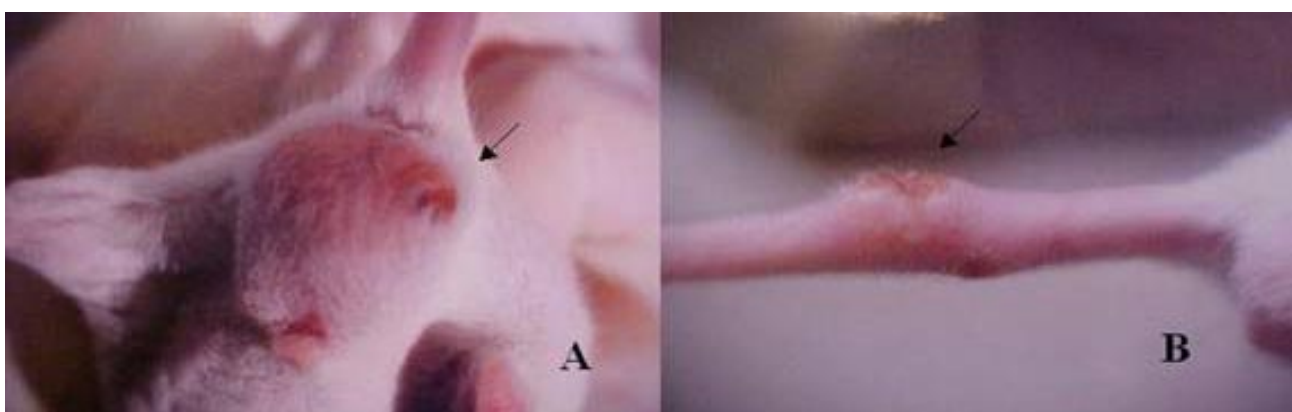


Figure 1. Mice inoculated with *Sporothrix schenckii* and showing disseminated sporotrichosis represented by lesions on the testicles of a mouse inoculated with the yeast form (A) and lesions on the tail of another mouse inoculated with the mycelial form (B).

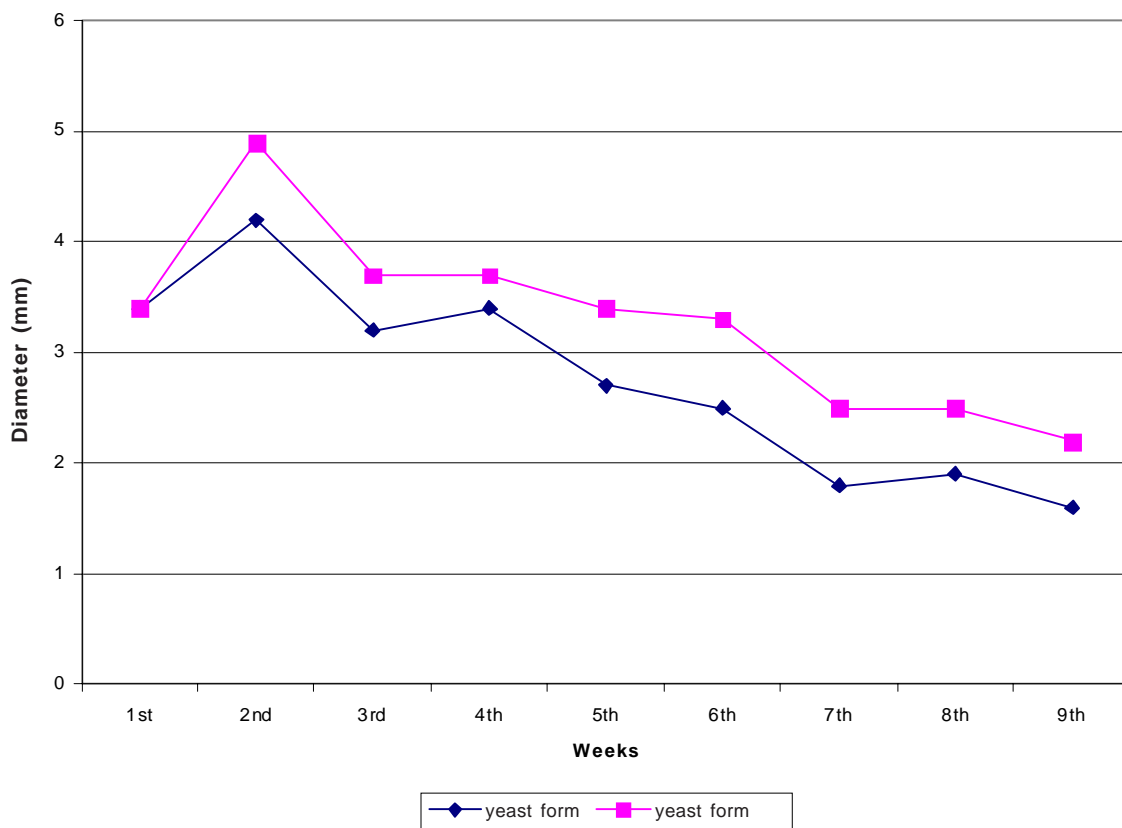


Figure 2. Average diameter of paw pad lesions observed for nine weeks in mice inoculated with the yeast form and mycelial form of *Sporothrix schenckii*.

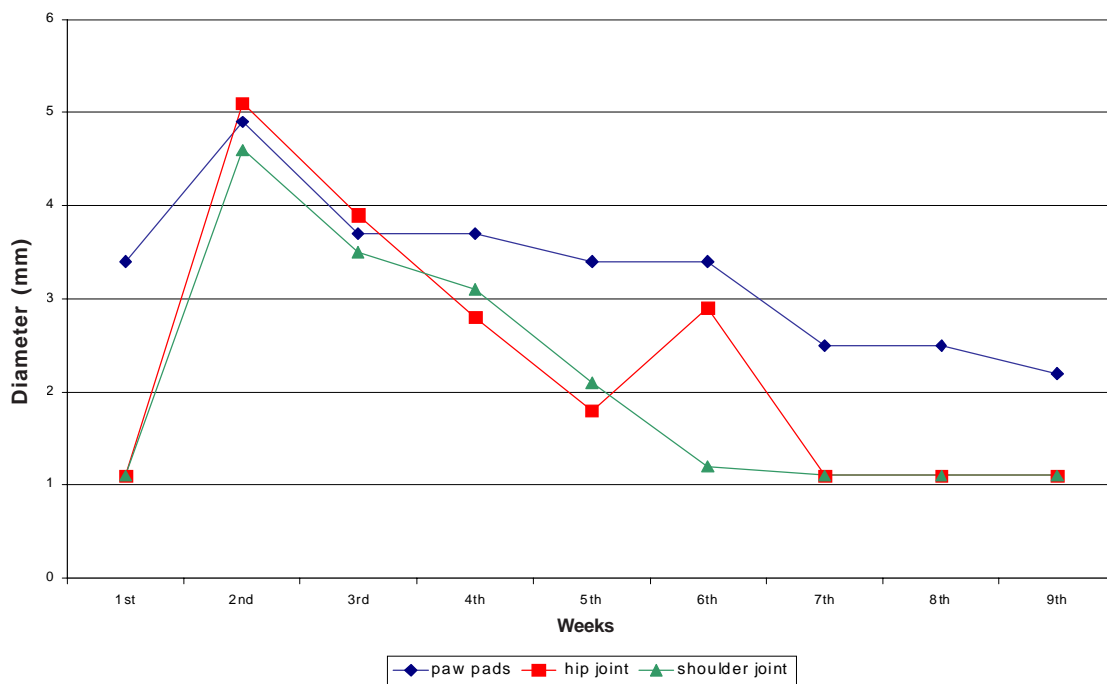


Figure 3. Average lesion diameter of the three inoculation sites (paw pad, shoulder and hip regions) collected during nine weeks in mice inoculated with the mycelial form of *Sporothrix schenckii*.

DISCUSSION

Similarities between groups inoculated with yeast and mycelial form of the fungus suggest that both acquired infections caused by handling dirt and plants [8,11] and feline injuries that usually have a great amount of yeast cells of *Sporothrix schenckii* [7,9,15] would potentially produce the same clinical picture. Results obtained in this work support the hypothesis that differences in clinical evolution of the disease would be related to the individual pathogenicity of each isolated and to the number of inoculated cells. It is known that skin late hypersensitivity tests using *S. schenckii* metabolic antigens extracted from yeast and mycelial forms did not show differences [9].

Although there were not statistically significant differences between groups Y and M, group M animals had more severe clinical pictures that last longer than the group Y animals. Results obtained allowed us to speculate that pathogenicity factors such as the presence of melanin (seeing in conidia used for group M) could have caused some barriers to the host's immune response. According to what was previously demonstrated, the *S. schenckii* conidia presence of DHN (dihydroxynaphthalene-melanin) decreases murine monocytes and macrophages phagocytic efficacy *in vitro* [14].

Furthermore it is important to consider that after inoculation of the mycelial form of *S. schenckii* it will occur a transition to the yeast form in the host beginning with destruction of hyphae and conidia gradual transformation to yeast cells [1]. During this transition there is a period, not defined yet, in which melanin remains in the fungal cell and it causes difficulties to the host's immune response what would make it easier for conidia to survive and multiply. In the other hand, although yeast cells could be initially more vulnerable to phagocytosis, this form of the fungus presents other factors for pathogenicity also responsible to trigger the infection.

Experimental sporotrichosis clinical development and the observed histopathology alterations were accordingly to other works [2,3,10,20]. However, scar reaction observed in this experiment was more intense in animals inoculated with the mycelial form (group M) possibly due to the fact that the larger lesions could have elicited a more intense epidermal and connective tissue proliferation.

The paw pads already tested in other studies [10,18] were considered the best site of inoculation

compared to hip and shoulder regions not previously tested according to the literature reviewed. The beginning of clinical signs occurred later in those new regions of inoculation possibly due to the lack of anatomic limits contributing to a smaller edema and to a bigger diffusion of the inflammatory reaction.

The four not inoculated animals did not develop sporotrichosis in spite of their permanent contact with potential contamination sources represented by the contact with infected animals, exudate and contaminated tissue fragments. The maintenance of the healthy state of those animals was favored by the absence of continuity processes through their skin and by their effective immune response.

There were classic examples of factor altering the immune response related to sporotrichosis. Such factors are stress, poor sanitary conditions and immunosuppressive diseases in groups of feline where several sporotrichosis cases were diagnosed during three years [12,17]. Besides this, human sporotrichosis has been linked to immunosuppressive diseases and corticoid therapy [11,13,16].

CONCLUSIONS

The development of a similar sporotrichosis clinical picture in both groups Y and M initially suggests that there is no difference between inocula of yeast or mycelial forms made from the same *Sporothrix schenckii* isolate. Also, results imply that the paw pads can be considered the preferential inoculation site in the murine model for experimental sporotrichosis. And it was demonstrated that contact with contaminated animals and materials is not enough to cause sporotrichosis in immunocompetent animals that have no evidence of skin lesions.

SOURCES AND MANUFACTURERS

¹ Brain-heart broth® - Merck KGaA, Frankfurter Str. 250, D-64293, Darmstadt, Germany

² Sabouraud 4% dextrose agar® - Merck KGaA, Frankfurter Str. 250, D-64293, Darmstadt, Germany

³ Bacto mycobiotic agar® - Difco Laboratories Detroit, Michigan, USA

ACKNOWLEDGMENTS

This work was in part supported by CNPq - Brazil (Grant No. 478000/01-4). M. O Nobre was supported by a doctoral fellowship from CAPES -Brazil.

REFERENCES

- 1 **Correa B., Gambale W., Paula C.R. & Palazzo S. 1991.** Morphogenesis of *Sporothrix schenckii* in vivo and in vitro through the method of viability by fluorescence. *Applied Fluorescence Technology*. 3:1-8.
- 2 **Findlay G.H. & Vismer H.F. 1986.** Studies in sporotrichosis: fungal morphogenesis and pathogenicity in differing environments. *Mycopathologia*. 96:115-122.
- 3 **González del Polania L.A.G., Alzate A. & Saraiva N. 1990.** Comportamiento experimental del *Sporothrix schenckii* y la *Leishmania mexicana* em el hamster. *Revista do Instituto de Medicina Tropical de São Paulo*. 32:319-324.
- 4 **Kwon-Chung K.J. & Bennett J.E. 1992.** Sporotrichosis. In: *Medical Mycology*. Philadelphia: Lea & Febiger, pp. 707-729.
- 5 **Lacaz C.S., Porto E., Heins-Vaccari E.M. & Melo N.T. 1998.** Identificação dos fungos. In: *Fungos, actinomicetos e algas de interesse médico*. São Paulo: Sarvier/Fapesp, pp. 326-330.
- 6 **Lacaz C.S., Porto E. & Martins J.E.C.M. 1991.** Esporotricose e outras micoses gomosas. In: *Micologia Médica*. São Paulo: Sarvier, pp. 233-247.
- 7 **Larsson C.E., Gonçalves M.A., Araujo V.C., Dagli M.L.Z., Correa B. & Fava Neto C. 1989.** Esporotricose felina: aspectos clínicos e zoonóticos. *Revista do Instituto de Medicina Tropical de São Paulo*.31: 351-358.
- 8 **Lopes O.J., Alves S.H., Mart C.R., Brum L.M., Westphalen J.B., Altermann M.J. & Prates F.B. 1999.** Epidemiology of sporotrichosis in the central region of Rio Grande do Sul. *Revista da Sociedade Brasileira de Medicina Tropical*.32: 541-545.
- 9 **Marques S.A., Camargo R.M.P., Haddad J.R., Marques M.E.A., Franco S.R.V.S. & Rocha N.S. 1998.** Human sporotrichosis: transmitted by feline. *Anais Brasileiros de Dermatologia*.73: 559-562.
- 10 **Mujica M.T., Agotegaray M., Canoba A., Delasoie P., Hauswirth S., Kociziki G., Tartabani M. & Alvarez D. 1992.** Esporotricose experimental en ratas. *Revista Argentina de Micología*.15: 7-12.
- 11 **Neto R.J.P., Machado A.A., Castro G., Quaglio A.S.S. & Martinez R. 1999.** Acquired immunodeficiency syndrome presenting as disseminated cutaneous sporotrichosis - case report. *Revista da Sociedade Brasileira de Medicina Tropical*.32: 57-61.
- 12 **Nobre M.O., Castro A.P., Caetano D., Souza L.L., Meireles M.C.A. & Ferreiro L. 2001.** Recurrence of sporotrichosis in cats with zoonotic involvement. *Revista Iberoamericana de Micología*.18: 137-140.
- 13 **Rocha M.M., Dassin T., Lira R., Lima E.L., Severo L.C. & Londero A.T. 2001.** Sporotrichosis in patient with AIDS: report of a case and review. *Revista Iberoamericana de Micología*.18:133-136.
- 14 **Romero-Martínez R., Wheeler M., Guerrero-Plata A., Rico G. & Torres-Guerrero H. 2000.** Biosynthesis and functions of melanin in *Sporothrix schenckii*. *Infection and Immunity*. 68: 3697-3703.
- 15 **Schubach T.M., Valle A.C.F., Gutierrez-Galhardo M.C., Monteiro P.C.F., Reis R.S., Zancopé-Oliveira R.M., Marzochi K.B.F. & Schubach A. 2000.** Isolation of *Sporothrix schenckii* from the nails of domestic cats (*Felis catus*). *Medical Mycology*.39: 147-149.
- 16 **Severo L.C., Festugato M., Bernardi C. & Londero, A.T. 1999.** Widespread cutaneous lesions due to *Sporothrix schenckii* in a patient under a long term steroids therapy. *Revista do Instituto de Medicina Tropical de São Paulo*.41: 59-62.
- 17 **Souza L.L. 2001.** *Sporothrix schenckii*: estudo epidemiológico em população de gatos. 32f. Pelotas, RS. Dissertação (Mestrado em Veterinária) - Programa de Pós-Graduação em Veterinária Preventiva, Universidade Federal de Pelotas.
- 18 **Tachibana T., Matsuyama M.I. & Mitsuyama M. 2001.** *Sporothrix schenckii* thermo-intolerant mutants losing fatal visceral infectivity but retaining high cutaneous infectivity. *Medical Mycology*. 39: 295-298.
- 19 **Velez H., Santamaria L., Guzman G., Escobar M., Giraldo R. & Gomez J. 1984.** Estudio comparativo de los antígenos micelial e levadura de *S. schenckii* mediante pruebas cutáneas. *Acta Médica Colombiana*.9: 150-156.
- 20 **Yoshike T., Lei P.C., Komatsuzaki H. & Ogawa H. 1993.** Antibody raised against extracellular proteinases of *Sporothrix schenckii* in *S. schenckii* inoculated hairless mice. *Mycopathologia*. 123: 69-73.

