

Case report

Open Access

Absence of diabetic retinopathy in a patient who has had diabetes mellitus for 69 years, and inadequate glycemic control: case presentation

Jorge Esteves*^{1,2}, Carolina Maurente da Rosa¹, Caroline Kaercher Kramer², Luiz Eduardo Osowski¹, Stéfano Milano¹ and Luís Henrique Canani²

Address: ¹Ophthalmology and otorhinolaryngology Division, Hospital de Clinicas de Porto Alegre, Porto Alegre, Brazil and ²Endocrinology Division, Hospital de Clinicas de Porto Alegre, Porto Alegre, Brazil

Email: Jorge Esteves* - estevesjf@terra.com.br; Carolina Maurente da Rosa - carolmaurente@yahoo.com; Caroline Kaercher Kramer - ckkramer@terra.com.br; Luiz Eduardo Osowski - leosowski@hotmail.com; Stéfano Milano - stefanomilano@yahoo.com.br; Luís Henrique Canani - luiscanani@yahoo.com

* Corresponding author

Published: 5 October 2009

Received: 24 April 2009

Diabetology & Metabolic Syndrome 2009, 1:13 doi:10.1186/1758-5996-1-13

Accepted: 5 October 2009

This article is available from: <http://www.dmsjournal.com/content/1/1/13>

© 2009 Esteves et al; licensee BioMed Central Ltd.

This is an Open Access article distributed under the terms of the Creative Commons Attribution License (<http://creativecommons.org/licenses/by/2.0>), which permits unrestricted use, distribution, and reproduction in any medium, provided the original work is properly cited.

Abstract

The main risk factors for the development and progression of diabetic retinopathy (DR) are chronic hyperglycemia, disease duration and systemic blood pressure. So far chronic hyperglycemia is the strongest evidence concerning the risk of developing DR. However there are some patients with poor metabolic control who never develop this diabetic complication. We present a case of a 73-year-old woman with type 1 diabetes mellitus, diagnosed 69 years ago. The patient is 73 years old, with no evidence of DR, despite poor glycemic control and several risk factors for DR. This case suggests the presence of a possible protection factor, which could be genetic.

Introduction

Diabetic retinopathy (DR) is the main cause of blindness in individuals aged 20-64 years, and accounts for 7.5% of the causes of adult work disability in Brazil. The risk of blindness is approximately 30-fold higher in people with diabetes mellitus (DM), compared to the population in general [1,2].

The most important risk factors for the development and progression of DR are chronic hyperglycemia, duration of the DM and systemic blood pressure levels [3-9]. Other possible risk factors are dyslipidemia, pregnancy, puberty and local ocular factors such as prior cataract surgery (facectomy) [10].

So far the most solid evidence for the risk of developing DR is chronic hyperglycemia [10-13]. After 20 years duration, there is some degree of DR in almost all patients with type 1 DM, 20% of them severe [14]. In insulin users with type 2 DM, the presence of DR occurs in approximately 84.5% of patients after 15 years of the disease [15].

However, there is great variability in the incidence of DR among patients with DM, and therefore it must be asked why some patients with poor metabolic control remain free of this complication.

We present the case of a 73-year old woman who has had type 1 DM for 69 years, without any evidence of DR,

despite inadequate glycemic control and several other risk factors for DR.

Case Report

White woman, 73 yrs old, nulliparous, type 1 DM diagnosed at age of 4 yrs, hypertension and dyslipidemia since the age of 44, and diagnosis of hypothyroidism since the age of 40. She smoked 20 cigarettes/day for 37 years. She has used insulin since diagnosis, currently associated with captopril 100 mg/day, simvastatin 40 mg/day, acetylsalicylic acid 200 mg/day and levotiroxine 75 µg/day, and has been regularly followed at the Endocrine Service and Ophthalmology Service at Hospital de Clínicas de Porto Alegre for the last 20 years. Since then, she has maintained inadequate glycemic control with recent mean HbA1c of 9.5% (reference values: 4 - 6.0%). During the follow up period the HbA1c measurement methods were changed at the hospital, and therefore figure 1A presents the values of HbA1c in percentage points above the upper limit of normality of the technique used, showing that the patient remained constantly above the target value. At physical examination during this period, she has had a mean blood pressure, of 124/84 mm Hg (Figure 1B) and maintains a body mass index of 24.2 kg/m². She informed that 23 years ago she had a myocardial infarction (confirmed by a fixed hypoperfusion area in the anterior wall of the myocardium at scintigraphy with dipyramidol), and 4 years ago she was submitted to peripheral artery revascularization surgery (aortofemoral bypass) and amputation of the second toe of the left foot. The latest evaluation of excretion of urinary albumin was 56.6 mg/24 hours (reference value <30 mg/24 hours).

At ophthalmologic examination, a visual acuity of 20/20 J1 was found in both eyes with the best correction. At biomicroscopy of the anterior segment pseudofascia were found in both eyes, with an ophthalmological history of

surgery of the cataract in the right eye on June 19, 2002 (extracapsular facectomy) and in the left eye on January 24, 2006 (phacoemulsification with intraocular lens implant). Measurement of intraocular pressure (IOP) was performed, always within the limits of normality, with a mean IOP of 14 mmHG in both eyes. At fundus examination of the eye, there was absence of signs of DR (Figure 2). The angiographic examination was also normal (Figure 3).

Discussion

The case shows the absence of DR in a patient with long duration DM, inadequate glycemic control, hypertension with irregular control and significant macrovascular disease.

Among the risk factors for the development of DM, chronic hyperglycemia and hypertension are the factors with the most solid evidence [1,2,16,17]. In the Wisconsin Epidemiologic Study of Diabetic Retinopathy (WESDR), the initial values of HbA1c were the most important risk factor for the onset and progression of DR [18,19]. Furthermore, hypertension is an important risk factor for the onset and progression of the disease, and in most studies it is an independent risk factor for DR.

The case reported illustrates that, despite the long duration of the disease, a few patients may not develop DR. Besides the duration of DM, age at diagnosis of type 1 DM appears to be related to the presence and severity of DR. Harvey et al observed a greater need for laser therapy in patients with a diagnosis of DM prior to the age of 15 years, and data from the EURODIAB suggest that the prepubertal duration of DM is related to the onset of microvascular complications[20,21]. The patient reported with the type 1 DM, besides long duration of the disease pre-

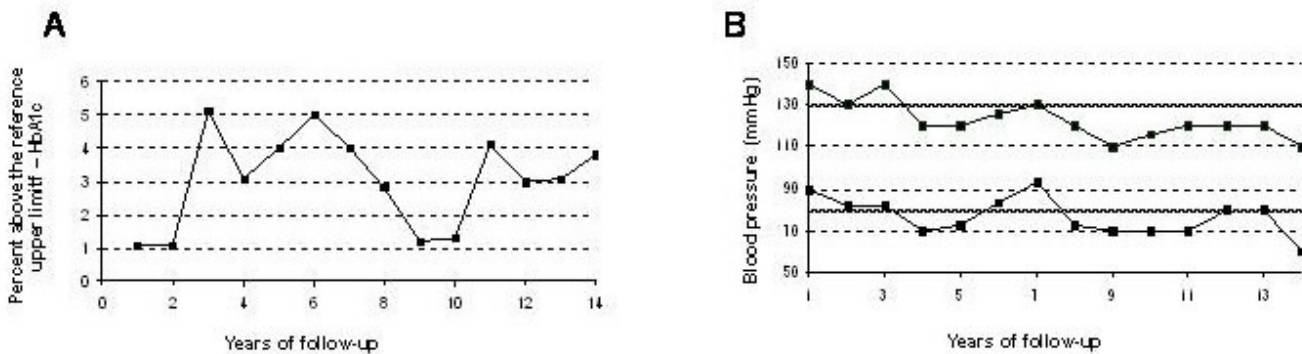


Figure 1
Patient's long-term glycemic and blood pressure control. **A.** Evolution of the HbA1c test during the years of follow up (in percentage points above the higher limit of the reference). **B.** Evolution of the control of blood pressure (systolic and diastolic) during the years of follow up compared to the values advocated.

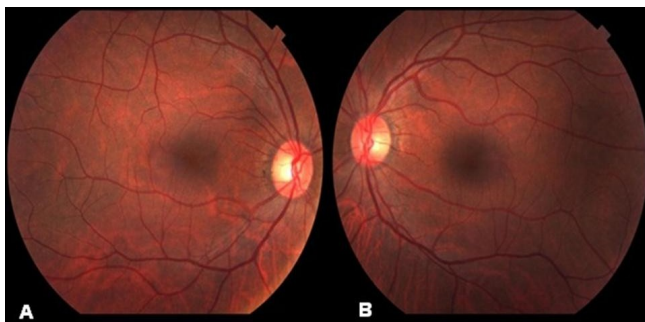


Figure 2
Eye fundus photograph showing the absence of diabetic retinopathy. A - Right eye B - Left eye.

sented an early diagnosis, which would further increase the risk of retinal injury.

The role of chronic hyperglycemia in the development of DR has been well established. Maintaining high levels in the HbA1c test is closely related to the development of DR. The accumulated incidence of DR 10 years after type

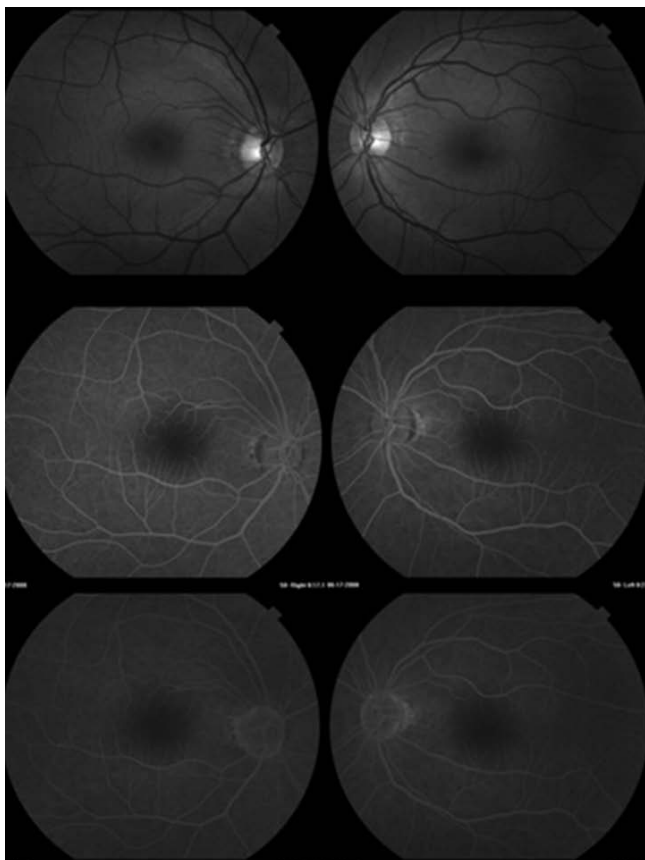


Figure 3
Study of normal angiofluoresceinography.

1 DM has been diagnosed is approximately 90% in patients with HbA1c between 10.2% and 11.5% [22]. Data from WESRD in type 1 DM demonstrate that for every 1% increment in the HbA1c test values, the risk of DR progression increases 1.21 fold [18,19]. The Diabetes Control and Complications Trial (DCCT) and United Kingdom Prospective Study (UKPDS) are randomized clinical trials that demonstrate the efficacy of glycemic control to prevent DR in patients with type 1 and type 2 DM, respectively [3,23]. Every 1% drop in the HbA1c test leads to an estimated reduction of 30% in the risk of microvascular complications [3,23].

The pressure levels also play an essential role in the pathogenesis of DR, increasing intraluminal pressure and worsening the blood-retinal barrier rupture [5-9]. In the WESRD study, diastolic pressure was associated with the presence of any degree of DR in patients with type 1 DM, and it is an independent risk factor for progression to proliferative DR [18,19]. The UKPDS demonstrated that blood pressure control is associated with the reduction of the DR incidence, and the relative risk of DR is 1.5 for systolic BP between 125-139 and 2.8 for systolic BP >140 mm Hg [23].

The presence of DR is associated with cardiovascular mortality both in patients with type 1 DM and in those with type 2 DM. The more severe DR forms being associated with a worse cardiovascular outcome. This evidence suggests that microvascular disease precedes macrovascular disease in a spectrum of a same disease triggered by chronic hyperglycemia, systemic hypertension, dyslipidemia and obesity [11,24].

Even with unequivocal evidence of the role of the risk factors cited previously, in the development of DR, a few as yet unidentified factors appear to counter this, protecting a few individuals from this complication. In the DCCT, approximately 40% of the patients with type 1 DM, without DR at the beginning of the study and HbA1c >9.8% did not present evidence of DR in 10 years of follow up [3].

The clinical course of DR is an example of the effect of the environmental component, in this case hyperglycemia, in the onset of the disease. On the other hand, proliferative DR, the most serious form of DR, affects individuals progressively, reaching a plateau after 20 years of DM. Moreover, intensive control of risk factors does not prevent the development of DR in all the patients [24]. In addition, a few ethnic groups have a higher frequency of DR. Hispanic and African-American patients present greater evidence of DR compared to Caucasian patients. We observed a higher proportion of severe DR among black Brazilian subjects compared to whites [25]. These obser-

vations suggest that genetically susceptible patients will develop DR more frequently. Studies of twin siblings with type 2 DM present a concordance for a 95% presence of DR. In patients with type 1 DM, the concordance is lower (67.7%). In both situations, this concordance is much higher than that expected from chance, suggesting a genetic component, and that this is more important in patients with type 2 DM. Studies of non-twin siblings showed that the presence of proliferative DR in one brother with type 2 DM increases the risk for the presence of proliferative DR in his brother with DM around three-fold. In the currently very fashionable studies on candidate genes, the associations of given genetic variants called genetic polymorphisms, with the presence of DR are evaluated. For instance, the genes of aldose reductase, RAGE, VEGF, ACE, NOS, ICAM-1 and PPAR- δ have been considered candidates for DR. A great diversity of results is observed among these genetic studies, with positive and negative associations with DR [2,26-31].

The case reported presents a woman who had had unsatisfactory glycemic control for a long time, hypertension with recent regular control, and severe macroangiopathy manifested by peripheral vasculopathy and cardiovascular disease, without any retinal involvement. This suggests that so far not all factors involved in the pathogenesis of the retinal injury in DM have been identified. More important, they call attention to the existence of locally protective, possibly genetic factor. The identification of this or these factors will enable a better understanding of the pathogenesis of DR and the institution of specific measures for the prevention and treatment of this complication of DM.

Competing interests

The authors declare that they have no competing interests.

Authors' contributions section

JE, CMR, LEO, and SM performed ophthalmologic evaluation, charts revision, data analysis and also wrote manuscript. CK and LHC performed clinical evaluation, data analysis, and wrote manuscript. JE and LHC did all manuscript coordination. All authors read and approved the final manuscript

Consent section

Written informed consent was obtained from the patient for publication of this case report and accompanying images. A copy of the written consent is available for review by the Editor-in-Chief of this journal.

References

- Boelter MCAM, Gross JL, Lavinsky J: **Fatores de risco para retinopatia diabética.** *Arq Bras Oftalmol* 2003, **66**:239-247.
- Esteves J, Laranjeira AF, Roggia MF, Dalpizol M, Scocco C, Kramer CK, Azevedo MJ, Canani LH: **[Diabetic retinopathy risk factors].** *Arq Bras Endocrinol Metabol* 2008, **52**:431-441.
- The effect of intensive treatment of diabetes on the development and progression of long-term complications in insulin-dependent diabetes mellitus. The Diabetes Control and Complications Trial Research Group.** *N Engl J Med* 1993, **329**:977-986.
- The effect of intensive diabetes treatment on the progression of diabetic retinopathy in insulin-dependent diabetes mellitus. The Diabetes Control and Complications Trial.** *Arch Ophthalmol* 1995, **113**:36-51.
- Leitao CB, Canani LH, Kramer CK, Moehlecke M, Pinto LC, Ricardo ED, Pinotti AF, Gross JL: **Blood pressure means rather than nocturnal dipping pattern are related to complications in Type 2 diabetic patients.** *Diabet Med* 2008, **25**:308-313.
- Leitao CB, Canani LH, Kramer CK, Boza JC, Pinotti AF, Gross JL: **Masked hypertension, urinary albumin excretion rate, and echocardiographic parameters in putatively normotensive type 2 diabetic patients.** *Diabetes Care* 2007, **30**:1255-1260.
- Kramer CK, Leitao CB, Azevedo MJ, Valiatti FB, Rodrigues TC, Canani LH, Gross JL: **Diabetic retinopathy is associated with early autonomic dysfunction assessed by exercise-related heart rate changes.** *Braz J Med Biol Res* 2008, **41**:1110-1115.
- Kramer CK, Leitao CB, Canani LH, Gross JL: **Impact of white-coat hypertension on microvascular complications in type 2 diabetes.** *Diabetes Care* 2008, **31**:2233-2237.
- Kramer CK, Leitao CB, Canani LH, Ricardo ED, Pinto LC, Valiatti FB, Gross JL: **Late afternoon blood pressure increase is associated with diabetic retinopathy in normotensive type 2 diabetes mellitus patients.** *Diabetes Res Clin Pract* 2009, **84**:e12-14.
- van Leiden HA, Dekker JM, Moll AC, Nijpels G, Heine RJ, Bouter LM, Stehouwer CD, Polak BC: **Risk factors for incident retinopathy in a diabetic and nondiabetic population: the Hoorn study.** *Arch Ophthalmol* 2003, **121**:245-251.
- Pambianco G, Costacou T, Ellis D, Becker DJ, Klein R, Orchard TJ: **The 30-year natural history of type 1 diabetes complications: the Pittsburgh Epidemiology of Diabetes Complications Study experience.** *Diabetes* 2006, **55**:1463-1469.
- Stratton IM, Kohner EM, Aldington SJ, Turner RC, Holman RR, Manley SE, Matthews DR: **UKPDS 50: risk factors for incidence and progression of retinopathy in Type II diabetes over 6 years from diagnosis.** *Diabetologia* 2001, **44**:156-163.
- Vitale S: **The Wisconsin Epidemiologic Study of Diabetic Retinopathy: what can we learn at 14 years?** *Ophthalmology* 1998, **105**:1799-1800.
- Krolewski AS, Warram JH, Rand LI, Christlieb AR, Busick EJ, Kahn CR: **Risk of proliferative diabetic retinopathy in juvenile-onset type I diabetes: a 40-yr follow-up study.** *Diabetes Care* 1986, **9**:443-452.
- Intensive blood-glucose control with sulphonylureas or insulin compared with conventional treatment and risk of complications in patients with type 2 diabetes (UKPDS 33). UK Prospective Diabetes Study (UKPDS) Group.** *Lancet* 1998, **352**:837-853.
- Henricsson M, Nystrom L, Blohme G, Ostman J, Kullberg C, Svensson M, Scholin A, Arnqvist HJ, Bjork E, Bolinder J, Eriksson JW, Sundkvist G: **The incidence of retinopathy 10 years after diagnosis in young adult people with diabetes: results from the nationwide population-based Diabetes Incidence Study in Sweden (DISS).** *Diabetes Care* 2003, **26**:349-354.
- Janka HU, Warram JH, Rand LI, Krolewski AS: **Risk factors for progression of background retinopathy in long-standing IDDM.** *Diabetes* 1989, **38**:460-464.
- Klein R, Klein BE, Moss SE, Davis MD, DeMets DL: **The Wisconsin epidemiologic study of diabetic retinopathy. II. Prevalence and risk of diabetic retinopathy when age at diagnosis is less than 30 years.** *Arch Ophthalmol* 1984, **102**:520-526.
- Klein R, Klein BE, Moss SE, Davis MD, DeMets DL: **The Wisconsin epidemiologic study of diabetic retinopathy. III. Prevalence and risk of diabetic retinopathy when age at diagnosis is 30 or more years.** *Arch Ophthalmol* 1984, **102**:527-532.
- Harvey JN, Allagoa B: **The long-term renal and retinal outcome of childhood-onset Type I diabetes.** *Diabet Med* 2004, **21**:26-31.
- Porta M, Sjoelie AK, Chaturvedi N, Stevens L, Rottiers R, Veglio M, Fuller JH: **Risk factors for progression to proliferative diabetic retinopathy in the EURODIAB Prospective Complications Study.** *Diabetologia* 2001, **44**:2203-2209.

22. Klein R, Klein BE, Moss SE, Davis MD, DeMets DL: **Glycosylated hemoglobin predicts the incidence and progression of diabetic retinopathy.** *Jama* 1988, **260**:2864-2871.
23. **Effect of intensive blood-glucose control with metformin on complications in overweight patients with type 2 diabetes (UKPDS 34).** UK Prospective Diabetes Study (UKPDS) Group. *Lancet* 1998, **352**:854-865.
24. **Tight blood pressure control and risk of macrovascular and microvascular complications in type 2 diabetes: UKPDS 38.** UK Prospective Diabetes Study Group. *Bmj* 1998, **317**:703-713.
25. Gerchman F, Zanatta CM, Burtet LM, Picon PX, Lisboa HR, Silveiro SP, Gross JL, Canani LH: **Vascular complications of black patients with type 2 diabetes mellitus in Southern Brazil.** *Braz J Med Biol Res* 2008, **41**:668-673.
26. Imperatore G, Hanson RL, Pettitt DJ, Kobes S, Bennett PH, Knowler WC: **Sib-pair linkage analysis for susceptibility genes for microvascular complications among Pima Indians with type 2 diabetes.** Pima Diabetes Genes Group. *Diabetes* 1998, **47**:821-830.
27. Hallman DM, Boerwinkle E, Gonzalez VH, Klein BE, Klein R, Hanis CL: **A genome-wide linkage scan for diabetic retinopathy susceptibility genes in Mexican Americans with type 2 diabetes from Starr County, Texas.** *Diabetes* 2007, **56**:1167-1173.
28. Felinski EA, Antonetti DA: **Glucocorticoid regulation of endothelial cell tight junction gene expression: novel treatments for diabetic retinopathy.** *Curr Eye Res* 2005, **30**:949-957.
29. dos Santos KG, Canani LH, Gross JL, Tschiedel B, Souto KE, Roisenberg I: **The catalase -262C/T promoter polymorphism and diabetic complications in Caucasians with type 2 diabetes.** *Dis Markers* 2006, **22**:355-359.
30. dos Santos KG, Canani LH, Gross JL, Tschiedel B, Souto KE, Roisenberg I: **The -106CC genotype of the aldose reductase gene is associated with an increased risk of proliferative diabetic retinopathy in Caucasian-Brazilians with type 2 diabetes.** *Mol Genet Metab* 2006, **88**:280-284.
31. Errera FI, Canani LH, Silva ME, Yeh E, Takahashi W, Santos KG, Souto KE, Tschiedel B, Roisenberg I, Gross JL, Passos-Bueno MR: **Functional vascular endothelial growth factor -634G>C SHP is associated with proliferative diabetic retinopathy: a case-control study in a Brazilian population of European ancestry.** *Diabetes Care* 2007, **30**:275-279.

Publish with **BioMed Central** and every scientist can read your work free of charge

"BioMed Central will be the most significant development for disseminating the results of biomedical research in our lifetime."

Sir Paul Nurse, Cancer Research UK

Your research papers will be:

- available free of charge to the entire biomedical community
- peer reviewed and published immediately upon acceptance
- cited in PubMed and archived on PubMed Central
- yours — you keep the copyright

Submit your manuscript here:
http://www.biomedcentral.com/info/publishing_adv.asp

