

Nail psoriasis treated with pulsed dye laser*

Juliano Peruzzo¹
Gabriela Maldonado²

Gabriela Czarnobay Garbin²
Tania Ferreira Cestari³

DOI: <http://dx.doi.org/10.1590/abd1806-4841.20175918>

Abstract: Nail changes are present in about 50% of psoriasis patients and tend to be refractory to conventional treatments. Pulsed dye laser has emerged as an alternative therapy. Our aim is to evaluate the efficacy of pulsed dye laser in nail psoriasis and the impact of treatment on quality of life. Fourteen patients were treated in monthly sessions for three months. The outcome assessment was made by the Nail Psoriasis Severity Index (NAPSI). The median improvement in the scores of the overall NAPSI, nail bed NAPSI, and nail matrix NAPSI were 44.2% ($P = 0.002$), 50% ($P = 0.033$) and 65.1% ($P = 0.024$), respectively.

Keywords: Lasers, dye; Laser therapy; Nails; Nail diseases; Psoriasis

Psoriasis is a chronic inflammatory disease with a 2% prevalence in the world population. Nail changes are present in approximately 50% of these patients and may affect up to 80% of them at some time during their lives.¹ Even the mild forms of the disease have a negative impact on oexclair quality of life.²

Nail psoriasis (NP) is noted for being resistant to treatment.³ Only 19.3% of the patients show significant improvement with the use of any topical treatment, and 77% of them would like to undergo a more effective treatment.²

Pulsed dye laser (PDL) has emerged as a therapeutic alternative for NP and has been established as a therapeutic choice for treating plaque psoriasis.⁴

This clinical trial was performed to assess the effectiveness of PDL in treating NP. The sample was calculated in 12 patients. To participate in this study, the patients could not have used systemic treatment or undergone phototherapy for at least eight weeks prior to the study, nor could they have undergone topical treatment for two weeks prior to the study or display onychomycosis or any other concomitant nail diseases.

Three PDL (Candela Vbeam Perfecta®, 595 nm pulsed dye laser) sessions were applied in four-week intervals, using the same application parameters for all participants: spot size 7 mm, pulse duration 0.45 ms, fluence 6J/cm².

Three clinical assessments were performed: before the first session, in the third session, and 90 days after the treatment had ended. In each assessment, the NAPSI, a score that objectively assesses the intensity of nail impairment, was calculated. In addition, patients answered the DLQI (Dermatology Life Quality Index) questionnaire before and after treatment and, in their last appointment, answered a treatment assessment questionnaire.

Fourteen patients participated in the study. The mean age \pm standard deviation was 44.1 \pm 16.4 years, and they had had nail changes for 7.2 \pm 6.49 years.

There was a significant reduction in NAPSI in follow-up (three months after the last session) compared to basal ($P = 0.002$) (Figure 1). The median (percentile 25 and percentile 75) improvement was 44.16% (7.08 and 65.63%) (Table 1). An improvement was also detected in the analysis of the nail bed NAPSI ($P = 0.033$). The median (p25 and p75) was 50% (1.67 and 73.86%).

Nail matrix changes were detected in ten of the 14 patients. The nail matrix NAPSI also revealed improvement if compared to the basal score ($P = 0.024$), with a median (p25 and p75) of 65.13% (24.36 and 89.29%). Among these patients, four reached NAPSI75 (an improvement of at least 75% in the score), and two of the patients' symptoms were resolved.

Received on 11.04.2016.

Approved by the Advisory Board and accepted for publication on 17.02.2017.

* Work performed at the University Hospital at the Federal University of Rio Grande do Sul (HCPA- UFRGS), Porto Alegre, RS, Brazil.

Financial support: Fundo de Incentivo à Pesquisa e Eventos (FIPE/HCPA).

Conflict of interest: none.

¹ Graduate Program in Surgery - School of Medicine at the Federal University of Rio Grande do Sul - Porto Alegre (RS), Brazil.

² Private practice - Porto Alegre (RS), Brazil.

³ Dermatology Service, Porto Alegre University Hospital at the Federal University of Rio Grande do Sul (HCPA-UFRGS) - Porto Alegre (RS), Brazil.

The pre-treatment DLQI median (p25 and p75) was 2.5 (1.0 and 11.5). The post-treatment DLQI median was 1 (0.8 and 3.5). The index improvement median was 40% (P = 0.007).

All patients mentioned having light pain during the laser application. Only one of them exhibited increased nail sensitivity that lasted longer than 24 hours.

Regarding the patients' level of satisfaction with the treatment, the median (p25 and p75) was 4 points (1.5 and 8.3). Eight patients (57.1%) reported having improvement with the treatment, and the improvement expectation was achieved for seven of the patients (50%). Thirteen patients (92.9%) would undergo the treatment again.

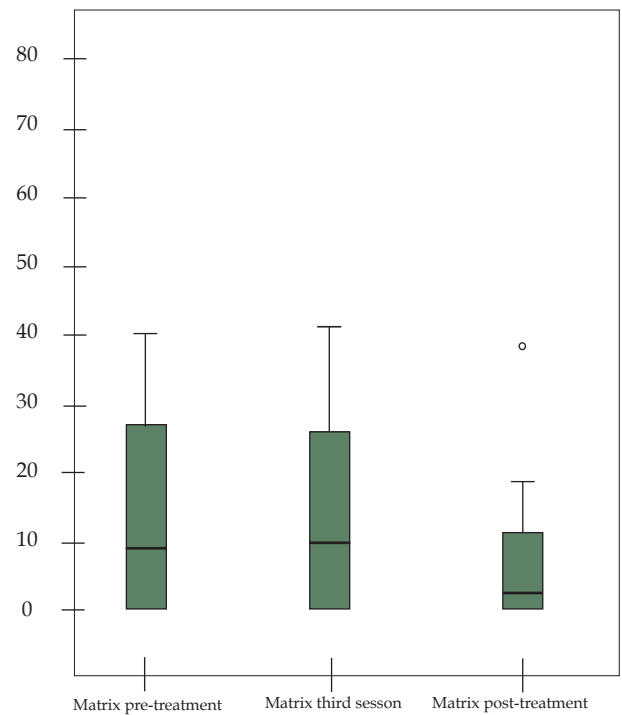
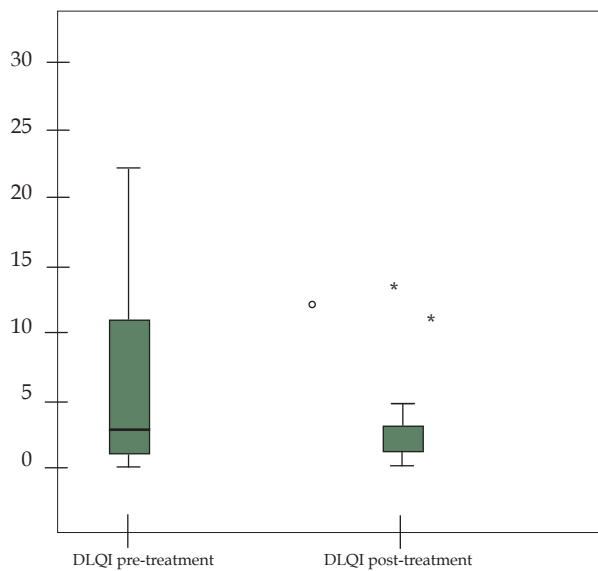
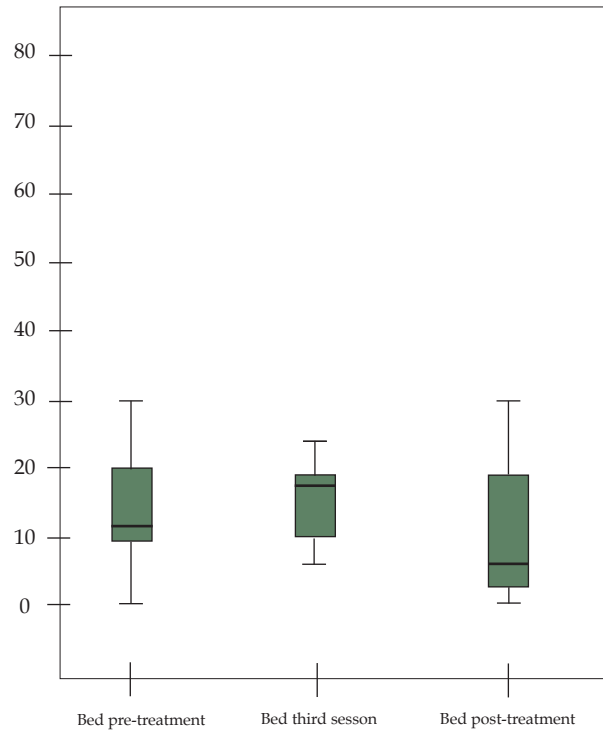
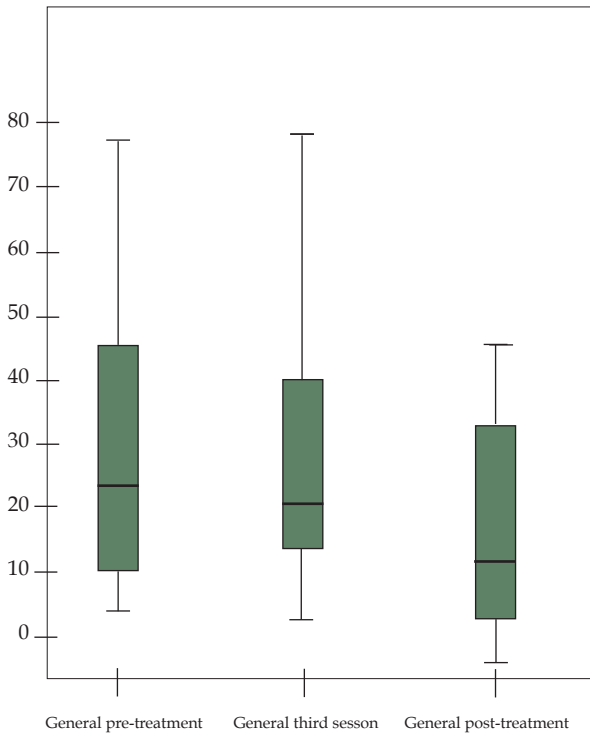


FIGURE 1: Box plot charts with the NAPSI and DLQI scores throughout the treatment

TABLE 1: Comparative table over time

	Pre	3 sessions	Post	P
General	22 (12 -41)	20 (15 -36)	14 (6 -29)	< 0.001
Matrix	9 (0 -29)	5 (0 -25)	2 (0 -12)	0.001
Bed	12 (10 -20)	14 (8 -17)	5 (2 -17)	0.011

Data presented by the median (P25-P75) and compared by the Friedman test.

One of the first changes noticed in NP is the increase in papillary dermis vasculature.⁴ Selective removal of abnormal vasculature by PDL based on selective photodermolysis may be beneficial to the treatment.⁵ In addition, PDL reduces the number of T-lymphocytes on the skin, helping to control inflammation.⁶ Given that this method is not practical and its cost is high, it has been suggested as an alternative treatment for localized lesions that are refractory to usual treatment, as well as for those in which systemic treatment would not be warranted.⁷

Some studies used PDL in NP showing improvement in NAPSII score at the end of the treatment.^{1,8,9,10} This study's results corroborate the results in the literature: seven (50%) patients reached NAPSII 50, while three (21.4%) reached NAPSII 75 at the end of the treatment. No patient presented the resolution of changes in all of the nails, which is consistent with the findings of Treewittayapoom *et al.*³, demonstrating an early response trend in matrix changes, when compared to those on the nail bed.

There is no consensus regarding the parameters to be used in the applications. Patients whose nails were subjected to energy with longer pulse duration reported a higher level of pain.³ We preferred the use of medium energy with lower pulse duration was preferred in order to cause an energy peak, increasing the chance of immediate vessel thrombosis, in addition to testing the efficacy of these parameters.

Despite a significant reduction in the NAPSII score, the improvement in nail aspects was only noticed by a little over half of the patients (57.1%), which may mean that the change was not as obvious or did not meet the patients' expectations.¹⁰ This also explains the fact that there have not been significant changes in DLQI results.

Regarding this study's limitations, the follow-up time could have been longer to allow for an assessment that would determine whether or not the observed response would be supported. Moreover, the use of a higher number of patients, and the existence of a control group, would increase the statistical power of the findings.

Given that there is no consensus, more studies are warranted to define the best application parameters. In addition, longer follow-up and treatment times could reveal results that are more striking. The observed results, however, allow one to consider the PDL to be a promising therapeutic modality, as it leads to clinical improvement, as well as to the improvement in the patient quality of life, in addition to presenting good application tolerability. □

REFERENCES

- Fernández-Guarino M, Harto A, Sánchez-Ronco M, García-Morales I, Jaén P. Pulsed dye laser vs. photodynamic therapy in the treatment of refractory nail psoriasis: a comparative pilot study. *J Eur Acad Dermatol Venereol.* 2009;23:891-5.
- de Jong EM, Seegers BA, Gulincx MK, Boezeman JB, van de Kerkhof PC. Psoriasis of the nails associated with disability in a large number of patients: results of a recent interview with 1,728 patients. *Dermatology.* 1996;193:300-3.
- Treewittayapoom C, Singvahanont P, Chanprapaph K, Haneke E. The effect of different pulse durations in the treatment of nail psoriasis with 595-nm pulsed dye laser: a randomized, double-blind, inpatient left-to-right study. *J Am Acad Dermatol.* 2012;66:807-12.
- De Leeuw J, Van Lingen RG, Both H, Tank B, Nijsten T, Martino Neumann HA. A Comparative Study on the Efficacy of Treatment with 585 nm Pulsed Dye Laser and Ultraviolet B-TL01 in Plaque Type Psoriasis. *Dermatol Surg.* 2009;35:80-91.
- Gümüsel M, Özdemir M, Mevlitoğlu I, Bodur S. Evaluation of the efficacy of methotrexate and cyclosporine therapies on psoriatic nails: a one-blind, randomized study. *J Eur Acad Dermatol Venereol.* 2011;25:1080-4.
- Yin N, Choudhary S, Nouri K. Pulsed dye laser for the treatment of nail psoriasis. *Cutis.* 2013;92:129-35.
- Erceg A, Bovenschen HJ, van de Kerkhof PC, Seyger MM. Efficacy of the pulsed dye laser in the treatment of localized recalcitrant plaque psoriasis: a comparative study. *Br J Dermatol.* 2006;155:110-4.
- Oram Y, Karıncaoğlu Y, Koyuncu E, Kaharaman F. Pulsed dye laser in the treatment of nail psoriasis. *Dermatol Surg.* 2010;36:377-81.
- Al-Mutairi N, Noor T, Al-Haddad A. Single Blinded Left-to-Right Comparison Study of Excimer Laser Versus Pulsed Dye Laser for the Treatment of Nail Psoriasis. *Dermatol Ther (Heidelb).* 2014;4:197-205.
- Huang YC, Chou CL, Chiang YY. Efficacy of pulsed dye laser plus topical tazarotene versus topical tazarotene alone in psoriatic nail disease: a single-blind, inpatient left-to-right controlled study. *Lasers Surg Med.* 2013;45:102-7.

MAILING ADDRESS:

Juliano Peruzzo
Rua Ramiro Barcelos, 2.350
Santa Cecilia,
90035-903 Porto Alegre – RS
Brazil
E-mail: julianoperuzzo@gmail.com

How to cite this article: Peruzzo J, Garbin GC, Maldonado G, Cestari TF. Nail psoriasis treated with pulsed dye laser. *An Bras Dermatol.* 2017;92(6): 885-7.